



Anti-LGALS3BP antibody-drug conjugate treatment induces durable and potent antitumor response in a preclinical model of adenoid cystic carcinoma

Emily Capone^{a,b,1}, Vittoria Perrotti^{c,j,1}, Ilaria Cela^{a,b}, Rossano Lattanzio^{a,b}, Lucrezia Togni^d, Corrado Rubini^d, Vito Carlo Alberto Caponio^e, Lorenzo Lo Muzio^e, Martina Colasante^f, Francesco Giansanti^f, Rodolfo Ippoliti^f, Stefano Iacobelli^g, Michael J. Wick^h, Nicole Spardy Burrⁱ, Gianluca Sala^{a,b,*}

^a Department of Innovative Technologies in Medicine & Dentistry, University "G. D'Annunzio" of Chieti-Pescara, Chieti, Italy

^b Center for Advanced Studies and Technology (CAST), University "G.D'Annunzio" of Chieti-Pescara, Chieti, Italy

^c Department of Medical, Oral and Biotechnological Sciences, University "G. d'Annunzio" Chieti-Pescara, Chieti, Italy

^d Department of Biomedical, Sciences and Public Health, Marche Polytechnic University, Ancona, Italy

^e Department of Clinical and Experimental Medicine, Foggia University, Foggia, Italy

^f Department of Life, Health and Environmental Sciences, University of L'Aquila, Coppito, Italy

^g MediaPharma s.r.l., Via Colonna 50/A, Chieti, Italy

^h XenoSTART, San Antonio, TX, USA

ⁱ Adenoid Cystic Carcinoma Research Foundation (ACCRF), Needham, MA, USA

^j Uda-TechLab, Research Center, University "G. d'Annunzio" of Chieti-Pescara, 66100 Chieti, Italy

ARTICLE INFO

Keywords:

Oral cancer
Adenoid cystic carcinoma
LGALS3BP
Antibody-drug conjugate
Targeted therapy
Immunotherapy

ABSTRACT

Objectives: Adenoid cystic carcinoma (ACC) is a rare type of cancer that typically arises from glandular tissues, most commonly in the salivary glands. Although relatively rare, it represents a serious clinical issue as the management of the disease is highly complex being the only therapeutic options represented by invasive surgery and/or radiotherapy. In the present study, we have explored the potential of galectin-3 binding protein (LGALS3BP) as a novel target for antibody-drug conjugate (ADC) therapy in ACC.

Materials and methods: RNAseq was conducted on a panel of 10 ACC patient-derived xenografts (PDX)s tissues and 6 normal salivary glands to analyze LGALS3BP gene expression. Protein expression was assessed in ACC PDX and primary tumor tissues using immunohistochemistry. Anti-LGALS3BP ADC named 1959-sss/DM4, was tested in high LGALS3BP expressing ACC PDX model ST1502B.

Results: RNAseq analysis revealed that LGALS3BP expression was highly expressed in ACC PDX tissues compared to normal salivary gland tissues. As evaluated by immunohistochemical analysis, LGALS3BP protein was found to be heterogeneously expressed in 10 ACC PDX and in tumor tissues derived from a cohort of 37 ACC patients. Further, treatment with 1959-sss/DM4 ADC led to durable tumor growth inhibition (TGI) in 100% of animals without observed toxicity.

Conclusions: Our study provides strong evidence that LGALS3BP is a promising therapeutic target for ACC, warranting further expedited preclinical and clinical investigation.

Abbreviations: ACC, Adenoid Cystic Carcinoma; ADC, Antibody Drug Conjugate; PDX, Patient-Derived Xenograft; TMA, Tissue MicroArray; IHC, Immunohistochemistry; ORR, Objective Response Rate; TGI, Tumor Growth Inhibition; EVs, Extracellular Vesicles.

* Corresponding author at: Laboratory of Clinical Biochemistry and Molecular Biology, Center for Advanced Studies and Technology (CAST), Department of Innovative Technologies in Medicine & Dentistry, "G. d'Annunzio" University of Chieti-Pescara, Via L. Polacchi 11, 66110 Chieti, Italy.

E-mail address: g.sala@unich.it (G. Sala).

¹ These authors contributed equally.

<https://doi.org/10.1016/j.oraloncology.2023.106635>

Received 7 September 2023; Received in revised form 24 October 2023; Accepted 15 November 2023

Available online 21 November 2023

1368-8375/© 2023 The Author(s). Published by Elsevier Ltd. This is an open access article under the CC BY license (<http://creativecommons.org/licenses/by/4.0/>).

Introduction

Adenoid cystic carcinoma (ACC) is a rare form of head and neck cancer predominantly affecting the major and minor salivary glands, and rarely the breast, trachea, and lacrimal glands [1]. Although ACC tends to have a slow-growing nature, its aggressiveness is documented by a low survival rate, with an average of only 20% of survivors at 20 years follow-up, due to propensity for perineural invasion, high incidence of recurrence and metastasis, with the lung being the most frequent metastasizing site [2], and significant resistance to anticancer therapeutic agents [3]. Therefore, the treatment of ACC typically involves a multidisciplinary approach and may vary depending on the location and stage of the cancer. The standard treatment for ACC remains surgery followed by radiation therapy, which may be occasionally used as the primary treatment when surgery is not feasible, or the tumor cannot be completely removed. Targeted therapy is still in the early stage of development supported by ongoing promising clinical trials. To date, there are no systemic chemotherapeutic agents to control such diseases, especially in advanced stages [4,5].

LGALS3BP (also known as Gal-3BP, 90 K, or Mac2-BP) is a secreted multifunctional glycoprotein that is highly expressed in a large number of cancerous specimens, while undetectable or poorly present in normal tissues, abundant on the surface of tumor-derived Extracellular Vesicles (EV)s in several solid cancers, and involved in tumoral progression mechanisms as invasion, migration, immune evasion and metastatic dissemination [6]. Recently, using melanoma, neuroblastoma and glioblastoma preclinical models, our group demonstrated that this glycoprotein represents a promising disease marker and a therapeutic target for ADC-based therapy [7–9]. This therapy combines the specificity of 1959-sss, an engineered humanized monoclonal antibody that recognizes LGALS3BP in the tumor extracellular microenvironment, with the cytotoxic effects of SH-DM4, a highly lipophilic analogue of maytansine that is able to diffuse into cells and to induce cell death.

In this study, we analyzed LGALS3BP expression in ACC specimens and studied the therapeutic potential of a high-expressing LGALS3BP PDX model. We explored the use of the secreted protein as a target for antibody-drug conjugates in this rare and orphan malignancy.

Materials and methods

ACC primary tumor and PDX samples

The cohort study was constituted by 37 patients who underwent surgical radical resection at the Department of Maxillofacial Surgery, “Ospedali Riuniti” General Hospital (Ancona, Italy) between 2010 and 2020. The average age of ACC patients was 58.7 ± 16.3 years, including 17 males and 20 females. To be included in this study, patients had to receive a histopathology-confirmed diagnosis of primary ACC of salivary glands. Patients below 18 years old or undergoing pre-operative radio- or chemotherapy were excluded. TNM classification was adopted according to the American Joint Committee on Cancer staging system (8th edition). Patients and tumor characteristics are summarized in Table 1. The study was reviewed and approved (authorization code: CRRM;2023;07;04_01) by “Comitato di Revisione della Ricerca Medica – CRRM. All patients provided written consent for the use of their specimens for research purposes; none were identifiable. The TMA containing tissue cores from 10 ACC PDX models was obtained from XenoSTART (San Antonio, TX).

Immunohistochemical staining

Formalin-fixed and paraffin-embedded tissue sections were stained using a goat polyclonal antibody raised against human LGALS3BP (1:400 dilution; incubation 60'; cat. number AF2226; R&D). Antigen retrieval was performed by microwave treatment at 750 W (10 min) in 10 mmol/l sodium citrate buffer (pH 6.0). The LSAB kit was used for

Table 1

Clinicopathological characteristics of ACC patients (n = 37).

Variable	Value (%)
Age at diagnosis (yr)	
Mean \pm SD	58.7 \pm 16.3
Median (Range)	57.0 (33–88)
Gender	
Male	17 (45.9)
Female	20 (54.1)
Histologic pattern	
Cribriform	22 (59.5)
Tubular	3 (8.1)
Solid	12 (32.4)
Tumor stage	
I	22 (59.5)
II	3 (8.1)
III	3 (8.1)
IV	9 (24.3)
R classification	
R0	9 (24.3)
R1	27 (73.0)
Unknown	1 (2.7)
Vascular invasion	
No	35 (94.6)
Yes	2 (5.4)
Perineural invasion	
No	22 (59.5)
Yes	15 (40.5)
Local infiltration	
No	28 (75.7)
Yes	9 (24.3)
Local relapse	
No	33 (89.2)
Yes	4 (10.8)
Metastasis	
No	32 (86.5)
Yes	5 (13.5)

signal amplification. DAB (3,3'-Diaminobenzidine) was used as chromogen. Immunohistochemically stained full-face sections were digitized by SlidePath using a NanoZoomer Digital Pathology (NDP) System (Hamamatsu, Welwyn Garden City, UK). Based on the distribution of LGALS3BP immunohistochemical expression, we have selected a cut-off value of 73%. This value was chosen arbitrarily and corresponds to the median (50th percentile) expression of LGALS3BP in our cohort of tumor cases, allowing us to dichotomize LGALS3BP expression.

RNAseq analysis

Ten ACC PDX tumors and six normal human salivary gland tissues were collected in RNAlater (ThermoFisher), processed using TruSeq Stranded mRNA Library Kit (Illumina) and gene expression levels were analyzed as previously described [10].

ACC PDX drug screening

All animal studies were performed at XenoSTART following Institutional Animal Care and Use Committee protocols. Early passage ST1502B tumor fragments (~70 mm³) were implanted subcutaneously in the flank of 5–7 week-old female nu/nu athymic nude mice (Charles River Laboratories) and the study initiated at a mean tumor volume of approximately 150–300 mm³. Mice were randomized to either 1959-sss/DM4 treatment (n = 5) or PBS as vehicle (n = 7) group, and received PBS or 1959-sss/DM4 (10 mg/kg, q3dx4) by intravenous injection via tail vein. Tumor dimensions were measured twice weekly using digital calipers and tumor volume was calculated using the following formula: Tumor Volume = width² × length × 0.52. The percent mean TGI was calculated using the following formula: %TGI = 1 - (Final average of Treatment group - Initial average of Treatment group) / (Final average of Control group - Initial average of Control group)

group). A partial responder was defined as any animal with tumor volume $\geq 50\%$ regression versus day 0 for two consecutive measurements over a period of ≥ 7 days during or at study completion.

Statistical analysis

The relations of LGALS3BP expression with clinicopathological features of the patients were evaluated by chi-squared test using the SPSS software (version 15.0; SPSS Inc., Chicago, IL). Differences in RNAseq and *in vivo* therapeutic study were analyzed using unpaired *t*-test with GraphPad Prism software (9.5 GraphPad Software Inc., San Diego, CA, USA). * $p = 0.02$ ** $p < 0.01$ *** $p < 0.001$ **** $p < 0.0001$.

Results

LGALS3BP expression in adenoid cystic carcinoma

With the aim to assess LGALS3BP as potential target in ACC for ADC therapy, mRNA levels were used for interrogating the gene expression in a panel of 10 ACC tumor samples and 6 normal salivary glands. As depicted in Fig. 1A, RNAseq analysis revealed a tumor-specific expression of LGALS3BP, as its mRNA expression resulted to be upregulated in ACC tumor samples compared to non tumoral specimens ($p = 0.02$).

Next, we evaluated the expression of LGALS3BP by immunohistochemistry using a TMA containing tissue cores from 10 ACC PDX models (Fig. 1B-C) [11]. Two PDXs (ACCX9 and ACCX11) were derived from tumors with solid histology, and four PDXs (ACCX2, ACCX6, ACCX5M1

and ACCX20M1) were derived from tumors with cribriform or tubular histologies. Histology data was not available for four ACC PDX models (ACCX15, ST2842, ST1502, and ST1502B). In the ACC LGALS3BP + cells, the expression of the protein was cytoplasmic. ACCx5M1, ACCx20M1, ST1502 and ST1502B PDX models showed positivity with high staining intensity (Fig. 1B-C). However, in 40% of cases, the staining intensity was low (ACCX2, ACCX15, ACCX6, ACCX11) and in 20% of ACC PDX cases (ACCX9 and ST2842), LGALS3BP expression was not present (Fig. 1B-C).

To confirm LGALS3BP expression in primary ACC tumor samples, we performed IHC analysis of LGALS3BP expression in a cohort of 37 ACC patients. Immunohistochemical analysis revealed that LGALS3BP is highly expressed in the cytoplasm of tumor cells in 92.1% of cases, in all the three histologic pattern subgroups (Fig. 2A). The proportion of LGALS3BP positive cells was in the range of 11–100%, with a mean and standard deviation of $63.6\% \pm 33.9$. To distinguish between low and high LGALS3BP expression, a cut-off value of 73% was used, which corresponds to the 50th percentile value (Fig. 2B). Therefore, ACC tumors with a percentage of stained cells $\leq 73\%$ were classified as low LGALS3BP, while those with a higher percentage were classified as high LGALS3BP. In this cohort of patients, the expression of LGALS3BP did not correlate with any clinicopathological variables and did not show a statistically significant impact on invasiveness or metastases. (Table 2).

Therapeutic activity of 1959-sss/DM4 ADC in ST1502B PDX model

In order to test whether LGALS3BP represents a potential therapeutic

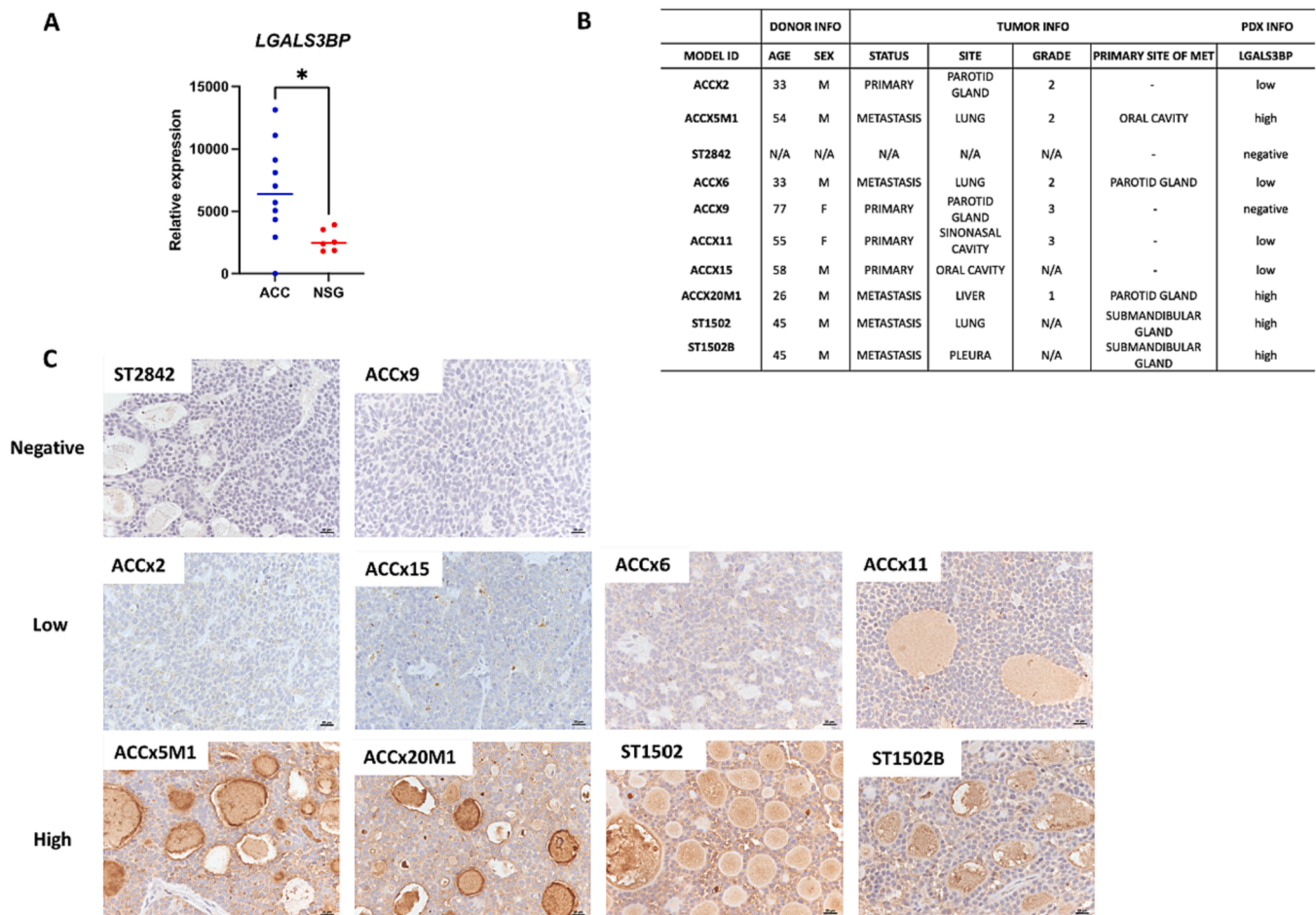


Fig. 1. A) Quantitative real-time PCR analysis of LGALS3BP expression in 10 ACC PDX samples vs 6 normal salivary gland (NSG) tissue samples. * $p = 0.02$) Table summarizing tumor information and LGALS3BP IHC staining intensity relative to 10 ACC-derived PDX and (C) relative representative images. Scale bar: 20 μ M. Magnification 40X.

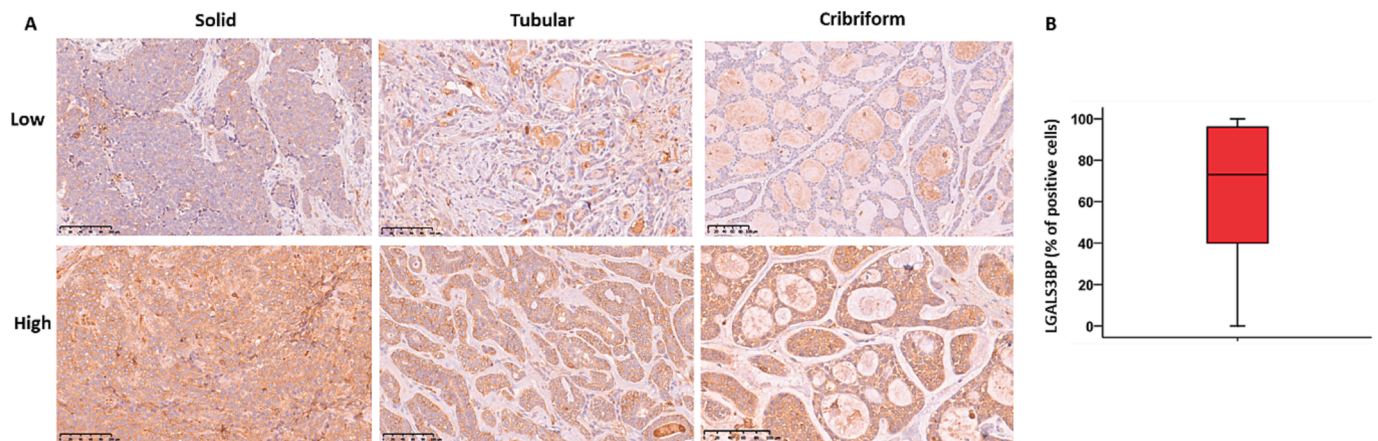


Fig. 2. A) Representative images of low/high LGALS3BP expression in solid, tubular and cribriform subtype of ACC primary tumors. Scale bar: 100 μ m. Magnification 20X. B) Box-and-whisker diagram displaying the percent of positive cancer cells stained with anti-LGALS3BP antibody. The upper and lower ends of boxes represent the 75th and 25th percentiles.

Table 2
LGALS3BP status according to the clinicopathological features of ACC patients.

Variable	LGALS3BP		P
	Low: n (%)	High: n (%)	
Gender			
Male	8 (47.05)	9 (52.9)	0.746
Female	11 (55.0)	9 (45.0)	
Histologic pattern			
Cribriform	9 (40.9)	13 (59.0)	0.306
Tubular	2 (66.6)	1 (33.3)	
Solid	8 (66.6)	4 (33.3)	
Tumor stage			
I	12 (54.5)	10 (45.4)	0.213
II	0 (0.0)	3 (100.0)	
III	1 (33.3)	2 (66.6)	
IV	6 (66.6)	3 (33.3)	
R classification			
R0	5 (55.5)	4 (44.4)	1.000
R1	14 (51.8)	13 (48.1)	
Vascular invasion			
No	18 (51.4)	17 (48.5)	1.000
Yes	1 (50.0)	1 (50.0)	
Perineural invasion			
No	14 (63.6)	8 (36.3)	0.099
Yes	5 (33.3)	10 (66.6)	
Local infiltration			
No	15 (53.5)	13 (46.4)	0.714
Yes	4 (44.4)	5 (55.5)	
Local relapse			
No	16 (48.4)	17 (51.5)	0.604
Yes	3 (75.0)	1 (25.0)	
Metastasis			
No	18 (56.2)	14 (43.7)	0.180
Yes	1 (20.0)	4 (80.0)	

target in ACC, we went on to evaluate the activity of 1959-sss/DM4 ADC [7] in a LGALS3BP-high expressing (Fig. 1B-C) ACC PDX model, ST1502B. Tumor-bearing animals treated with 1959-sss/DM4 at the dose of 10 mg/kg twice/weekly for a total of 3 administrations displayed durable tumor growth inhibition (TGI) reaching >100% at the end of the experiment (day 56; $p < 0.0001$) with one partial tumor regression compared to PBS control (Fig. 3A-C). In cases where 1959-sss/DM4 treatment was administered, as opposed to cases where no treatment was given (i.e., control cases), there was evidence of single-cell degeneration and atrophy with eosinophilic material in the acini from ACC, along with an interstitial fibrous stroma reaction (Fig. 4). Importantly, 1959-sss/DM4 administered at 10 mg/kg was well tolerated with maximum weight loss in any group not greater than 7% and no drug-

related deaths observed in treated mice (Fig. 3D).

Discussion

ACC is a relative rare salivary gland tumor arising from the head & neck region. Although surgery and radiation generally lead to good local control at the primary tumor site, approximately 50% of patients will go on to develop metastases, most frequently to the lungs. The treatment and management of ACC represent a serious clinical challenge since, despite the great effort made in identifying valid therapeutic targets, no satisfactory results have been obtained from the numerous clinical trials that have taken place over the last twenty years [12].

The most well-known and studied molecular targets involved in ACC growth and progression are the MYB/NFIB [10,13] translocation, the c-KIT and EGFR tyrosine kinase receptors and NOTCH1 activating mutations [14,15]. The use of immunotherapy has also been evaluated primarily with nivolumab alone or in combination with ipilimumab, however no one of these systemic therapeutics have demonstrated clinical activity in terms of objective response rate (ORR) [16]. In the present study, we focused our attention on a novel target, i.e. the secreted glycosylated protein named LGALS3BP, which has been found to be overexpressed in a variety of cancers, including head & neck [17]. Several observations suggest that the protein is largely overexpressed in the tumor tissue compared to the non-neoplastic counterpart, making LGALS3BP a suitable target for ADC-based therapy [6,7,9].

Our previous studies showed that EVs-associated LGALS3BP can be efficiently targeted by a specific antibody-drug conjugate constituted by a humanized engineered monoclonal antibody directly linked to maytansinoid derivatives, DM3 or DM4 [8,9]. The ADC, carrying DM4 as payload and named 1959-sss/DM4, has demonstrated potent and durable antitumor activity in melanoma, neuroblastoma and glioblastoma preclinical models [7–9]. ADCs belong to one of the fastest growing groups of anticancer agents under clinical development in oncology, where indeed promising preclinical and clinical results have been obtained in several indications, including head & neck cancers [18]. In the last years more than 21 ADCs have entered in mid/late stage clinical trials and 14 of them received FDA approval to date [4]. The mechanism of action postulated for 1959-sss/DM4 based ADC is based on its accumulation in the tumor milieu where density of soluble and cancer EVs-associated LGALS3BP antigen is high, and reducing conditions permits release of DM4 toxin, diffusion through membranes of cancer and cancer-associated cells and exploitation of its toxic activity. In detail, the ADC is designed to have a fixed drug-antibody ratio (DAR) of 2, which is obtained by the direct and site-specific conjugation of the thiol-containing DM4 (SH-DM4) to the two residual light chain cysteines

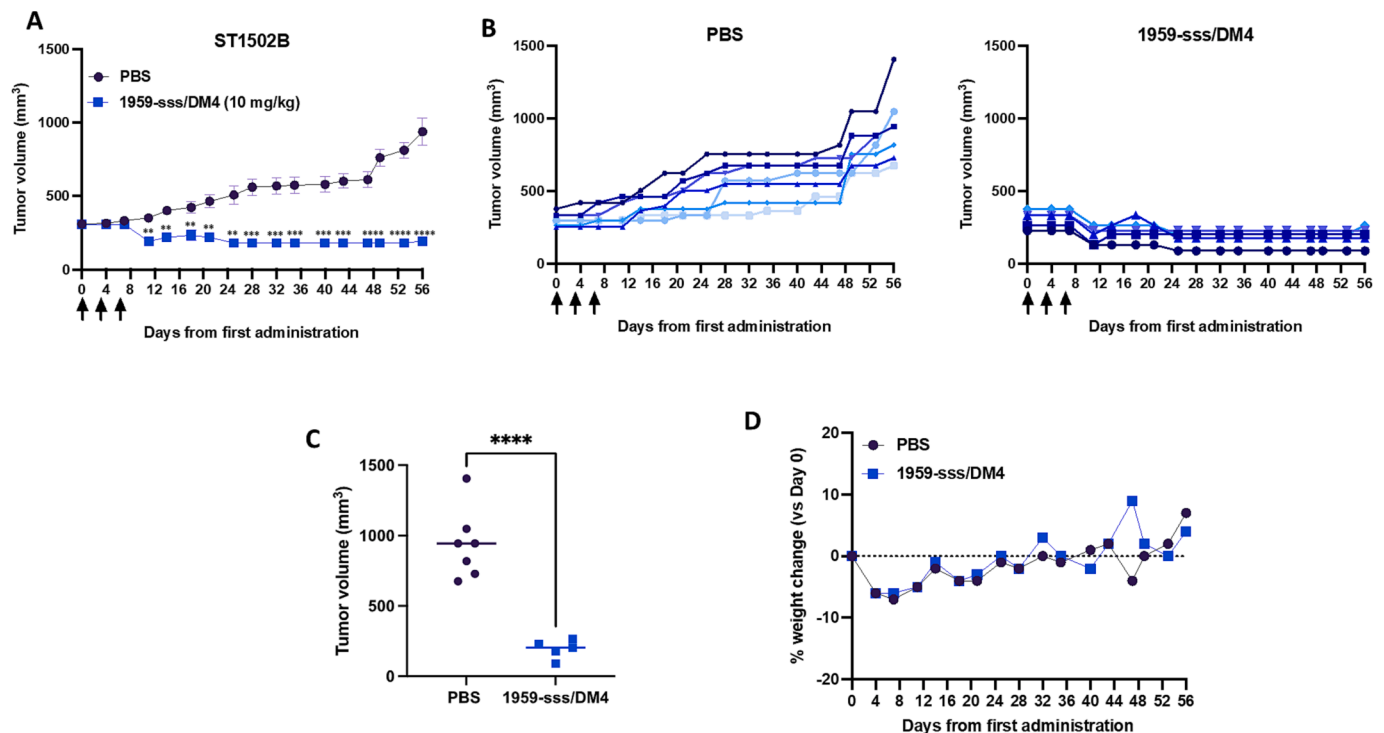


Fig. 3. A) Nu/nu athymic nude mice harboring ST1502B PDX were treated with vehicle ($n = 7$; PBS) or 1959-sss/DM4 ($n = 5$) at 10 mg/kg twice weekly for a total of three injections. Data are shown as mean \pm standard error. $**p < 0.01$ $***p < 0.001$ $****p < 0.0001$. B) Individual tumor growth curves in the ST1502B PDX ACC model. C) Volumetric scatter plot showing individual tumors on day 56. $****p < 0.0001$. D) Percentage of body weight change in mice during the therapeutic study.

available on the engineered humanized version of 1959 antibody, i.e. 1959-sss [9]. The release of the cytotoxic moiety of this type of linkerless non-internalizing ADC occurs through the disulfide bond breakage induced by high concentration of reductant species resident in the extracellular tumor microenvironment [19]. Once released in the extracellular space, the payload induces cell death possibly increasing the amount of reductant species in the tumor microenvironment. This in turn, would promote further payload release and cell death triggering a “chain reaction”. In line with this hypothesized mechanism, 1959-sss/ADC achieved long-lasting and complete remission in several preclinical models [8,9,17]. In this work, RNAseq analysis on 10 ACC patient-derived xenografts (PDXs) compared to 6 normal salivary glands revealed a high LGALS3BP expression only in tumoral specimens, then confirmed at the protein level in many of the same ACC-derived PDX samples by IHC analysis. High LGALS3BP expression was then validated in primary ACC tumor tissues derived from a cohort of 37 ACC patients, resulting in a positivity in 92.1% of cases belonging to all three histologic pattern subgroups, with a mean LGALS3BP positivity of $63.6\% \pm 33.9$. Furthermore, a high and homogenous LGALS3BP expressing PDX model (ST1502B) was chosen to run a therapeutic study using 1959-sss/DM4, in which $>100\%$ tumor growth inhibition was observed in animals treated with 1959-sss/DM4 compared to control animals. The lack of available preclinical models is one of the major challenges for investigators in developing new therapies for ACC. Indeed, while a number of ACC cell lines have been developed, none are commercially available, and only ACC patient derived xenograft (PDX) models have been shown to be a viable model for preclinical studies [20].

Given the shortage of preclinical models and clinical patients specimens, as well as valid systemic therapeutic options, we believe that our results represent an important step forward for preclinical research in this complex disease. Recently, the radioimmunoconjugate [89Zr]Zr-DFO-1959 was generated, which was successfully applied in immunopET of melanoma PDX models, representing a promising useful tool for clinical imaging as companion theranostic agent in support of

LGALS3BP-targeted therapies [21]. Homogeneous expression of LGALS3BP within ACC tumor tissue has been demonstrated here, thus representing a suitable malignancy for use of radioimmunoconjugate [89Zr]Zr-DFO-1959, in order to expand the imaging armamentarium for its early diagnosis. The 1959-sss/based ADC is at the preclinical stage although preliminary toxicology studies have been conducted in rabbit model [9]. Generation of stable cell line producing the engineered 1959-sss antibody as well as scale-up of the site-specific linker-less conjugation process, should be developed for clinical purpose.

A potential limitation of our study relies in the fact that only one PDX model was used for therapeutic studies. Additional preclinical studies will be necessary to fully validate the therapeutic potential of this new compound for ADC-based therapy in ACC. It is important to underline that in the selected model long-lasting response was observed in 100% of treated animals. This represents a meaningful therapeutic activity which is not common to observe in refractory indolent tumors like ACC for which no significantly effective systemic therapy has been discovered to date.

In sum, our study offers solid proof of principle that LGALS3BP protein is a promising therapeutic target for antibody drug conjugate-based therapy deserving further expedited preclinical and clinical investigation.

Ethics approval and consent to participate

The study was reviewed and approved (authorization code: CRRM;2023;07;04_01) by “Comitato di Revisione della Ricerca Medica – CRRM. All patients provided written consent for the use of their specimens for research purposes; none were identifiable.

Consent for publication

Not applicable.

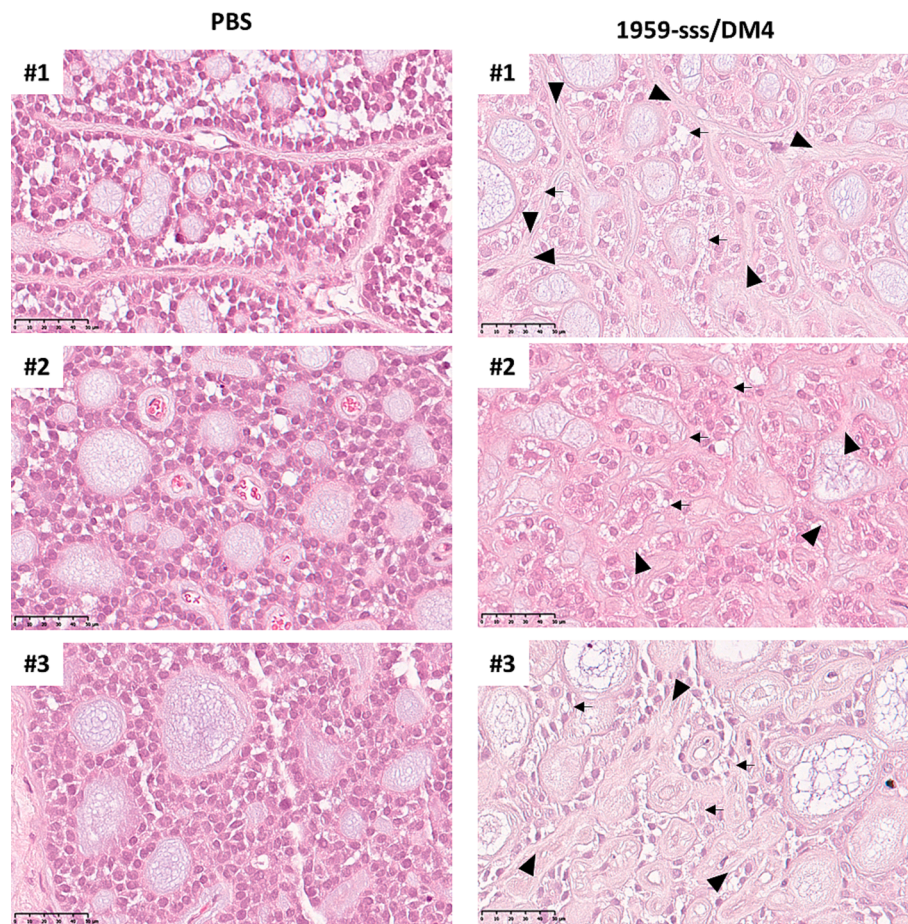


Fig. 4. Representative H&E staining images of ST1502B xenograft. Scale bar: 50 μ m. Magnification 40X. Examples of cell degeneration and atrophy (black arrows) and interstitial fibrous stroma reaction (black arrowheads) are shown.

Availability of data and materials

All data generated or analyzed during this study are included in this published article.

Funding

This work was supported by Fondazione-AIRC: GS [IG 2021 id 25696] and Adenoid Cystic Carcinoma Research Foundation (ACCRF).

Declaration of Competing Interest

The authors declare that they have no known competing financial interests or personal relationships that could have appeared to influence the work reported in this paper.

Acknowledgments

We thank all medical doctors, nurses and patients who were involved in the collection of the samples. Francesco Del Pizzo is kindly acknowledged for helping with the immunohistochemistry assays.

References

- [1] Dillon PM, et al. Adenoid cystic carcinoma: A review of recent advances, molecular targets, and clinical trials. *Head Neck* 2016;38(4):620–7.
- [2] Kokemueller H, et al. Adenoid cystic carcinoma of the head and neck—a 20 years experience. *Int J Oral Maxillofac Surg* 2004;33(1):25–31.
- [3] Sahara S, Herzog AE, Nor JE. Systemic therapies for salivary gland adenoid cystic carcinoma. *Am J Cancer Res* 2021;11(9):4092–110.
- [4] Wagner VP, et al. Drug-based therapy for advanced adenoid cystic carcinoma: Current landscape and challenges based on an overview of registered clinical trials. *Crit Rev Oncol Hematol* 2023;181:103886.
- [5] Miller LE, et al. A Contemporary Review of Molecular Therapeutic Targets for Adenoid Cystic Carcinoma. *Cancers (Basel)* 2022;14(4).
- [6] Capone E, Iacobelli S, Sala G. Role of galectin 3 binding protein in cancer progression: a potential novel therapeutic target. *J Transl Med* 2021;19(1):405.
- [7] Dufresine B, et al. Extracellular LGALS3BP: a potential disease marker and actionable target for antibody-drug conjugate therapy in glioblastoma. *Mol Oncol* 2023.
- [8] Capone E, et al. Targeting Vesicular LGALS3BP by an Antibody-Drug Conjugate as Novel Therapeutic Strategy for Neuroblastoma. *Cancers (Basel)* 2020;12(10).
- [9] Giansanti F, et al. Secreted Gal-3BP is a novel promising target for non-internalizing Antibody-Drug Conjugates. *J Control Release* 2019;294:176–84.
- [10] Andersson MK, et al. ATR is a MYB regulated gene and potential therapeutic target in adenoid cystic carcinoma. *Oncogenesis* 2020;9(1):5.
- [11] Moskaluk CA, et al. Development and characterization of xenograft model systems for adenoid cystic carcinoma. *Lab Invest* 2011;91(10):1480–90.
- [12] Ardolino L, et al. Advanced Adrenocortical Carcinoma (ACC): a Review with Focus on Second-Line Therapies. *Horm Cancer* 2020;11(3–4):155–69.
- [13] Persson M, et al. Recurrent fusion of MYB and NFIB transcription factor genes in carcinomas of the breast and head and neck. *Proc Natl Acad Sci U S A* 2009;106(44):18740–4.
- [14] Xie M, et al. Alterations of Notch pathway in patients with adenoid cystic carcinoma of the trachea and its impact on survival. *Lung Cancer* 2018;121:41–7.
- [15] Ferrarotto R, Heymach JV. Taking it up a NOTCH: a novel subgroup of ACC is identified. *Oncotarget* 2017;8(47):81725–6.
- [16] Kacew AJ, Hanna GJ. Systemic and Targeted Therapies in Adenoid Cystic Carcinoma. *Curr Treat Options Oncol* 2023;24(1):45–60.
- [17] Cela I, et al. LGALS3BP is a potential target of antibody-drug conjugates in oral squamous cell carcinoma. *Oral Dis* 2023.
- [18] Perrotti V, et al. Therapeutic Potential of Antibody-Drug Conjugate-Based Therapy in Head and Neck Cancer: A Systematic Review. *Cancers (Basel)* 2021;13(13).

- [19] Ashman N, Bargh JD, Spring DR. Non-internalising antibody-drug conjugates. *Chem Soc Rev* 2022;51(22):9182–202.
- [20] Nightingale J, et al. Adenoid cystic carcinoma: a review of clinical features, treatment targets and advances in improving the immune response to monoclonal antibody therapy. *Biochim Biophys Acta Rev Cancer* 2021;1875(2):188523.
- [21] Keinanen O, et al. Visualizing Galectin-3 Binding Protein Expression with ImmunoPET. *Mol Pharm* 2023;20(6):3241–8.