UNIVERSITÀ POLITECNICA DELLE MARCHE
Repository ISTITUZIONALE

Cerebellar Functional Connectivity Reorganization in a Split-Brain Patient

This is the peer reviewd version of the followng article:

Original
Cerebellar Functional Connectivity Reorganization in a Split-Brain Patient / Iammarino, E., Marcantoni, I., Reversi, L., Mariotti, F., Piccolantonio, G., Foschi, N., Ghoushi, M., Devivo, L., Polonara, G., Fabri, M., Burattini, L.. - (2025), pp. 1176-1181. (2025 IEEE International Conference on Metrology for eXtended Reality, Artificial Intelligence and Neural Engineering (MetroXRAINE) Ancona, Italy 22-24 October 2025) [10.1109/MetroXRAINE66377.2025.11340196].

Availability:
This version is available at: 11566/352252 since: 2026-01-27T17:01:56Z

Publisher:
IEEE

Published
DOI:10.1109/MetroXRAINE66377.2025.11340196

Terms of use:

The terms and conditions for the reuse of this version of the manuscript are specified in the publishing policy. The use of copyrighted works requires the consent of the rights' holder (author or publisher). Works made available under a Creative Commons license or a Publisher's custom-made license can be used according to the terms and conditions contained therein. See editor's website for further information and terms and conditions.
This item was downloaded from IRIS Università Politecnica delle Marche (https://iris.univpm.it). When citing, please refer to the published version.

Publisher copyright:

IEEE - Postprint/Author's Accepted Manuscript

©2025 IEEE. Personal use of this material is permitted. Permission from IEEE must be obtained for all other uses, in any current or future media, including reprinting/republishing this material for advertising or promotional purposes, creating new collective works, for resale or redistribution to servers or lists, or reuse of any copyrighted component of this work in other works. To access the final edited and published work see 10.1109/MetroXRAINE66377.2025.11340196

(Article begins on next page)

17 October 2026

Cerebellar Functional Connectivity Reorganization in a Split-Brain Patient

Erica Iammarino
Dept. Information Eng
Università Politecnica delle Marche
Ancona, Italy
e.iammarino@pm.univpm.it

Ilaria Marcantoni
Dept. Information Eng
Università Politecnica delle Marche
Ancona, Italy
i.marcantoni@staff.univpm.it

Luca Reversi
Dept. Radiological Sciences
Az. Ospedaliera-Universitaria Marche
Ancona, Italy
luca.reversi@ospedaliriuniti.marche.it

Francesco Mariotti
Dept. Odontostomat Spec Clin Sciences
Università Politecnica delle Marche
Ancona, Italy
dottfrancescomariotti@gmail.com

Giusi Piccolantonio
Dept. Eng for Innovation Medicine
Università di Verona
Verona, Italy
giusi.piccolantonio@univr.it

Nicoletta Foschi
Dept. Neurological Sciences
Az. Ospedaliera-Universitaria Marche
Ancona, Italy
n.foschi@ospedaliriuniti.marche.it

Mojgan Ghoushi
Dept. Radiological Sciences
Az. Ospedaliera-Universitaria Marche
Ancona, Italy
mojgan.ghoushi@ospedaliriuniti.marche.it

Luisa De Vivo
School of Pharmacy
Università of Camerino
Camerino, Italy
luisa.devivo@unicam.it

Gabriele Polonara
Dept. Odontostomat Spec Clin Sciences
Università Politecnica delle Marche
Ancona, Italy
g.polonara@staff.univpm.it

Mara Fabri
Dept. Life and Environtal Sciences
Università Politecnica delle Marche
Ancona, Italy
m.fabri@staff.univpm.it

Laura Burattini
Dept. Information Eng
Università Politecnica delle Marche
Ancona, Italy
l.burattini@univpm.it

***Abstract*— The Functional Connectivity (FC) assesses the functional relationships between different brain regions. Interhemispheric FC is assumed to be specifically supported by the corpus callosum (CC). This study aims to investigate FC between cerebellum and resting state networks (RSNs), as well as intra-cerebellar FC, in a patient who underwent surgical resection of CC and in a healthy control. The investigation contributes to verify the hypothesis of a compensatory cerebellar role in maintaining a certain degree of interhemispheric FC after callosal resection. Anatomical and functional magnetic resonance images were analyzed using CONN. After standard preprocessing, the brain was parcellated into 30 cortical RSN regions of interest (ROIs) based on the Human Connectome Project (HCP) networks, and the cerebellum was parcellated into 18 ROIs according to the Automated Anatomical Labeling (AAL) atlas. FC was evaluated by computing the Fisher z-transformed bivariate correlation coefficients, and statistical differences were assessed by Wilcoxon signed rank test. Distinct patterns of FC were observed between patient and healthy control, both within the cerebellum and between cerebellar and cortical RSN ROIs. The patient's cerebellar FC with RSN ROIs was statistically different from that of the control (in most instances higher) in 11 cerebellar ROIs, 7 of which in the right of the cerebellum and 4 in the left. The patient intra-cerebellar FC was also statistically different from that of the control (in most instances higher). These results suggest that the cerebellum may have a role in the maintenance of interhemispheric FC after surgical resection of the CC.**

Keywords—split brain, callosotomy, connectivity matrix

I. Introduction

In neuroscience, the cerebral resting state refers to a condition in which the brain is active and alert but not engaged in a specific task. This condition is very important to be studied because spontaneous brain activity provides insights into the connections established among different cortical regions [1]. These functional relationships define the functional connectivity (FC) of the brain. FC analysis can be performed through functional magnetic resonance imaging (fMRI), an imaging technique based on local variation in blood flow of brain areas, which corresponds to a signal over time called Blood Oxygen Level Dependent (BOLD). The FC is quantified through the correlation of the BOLD signal in two or more brain areas anatomically separated, and it is often assessed in resting state conditions. The correlation of BOLD signal trends in the involved brain areas is interpreted as an index of relationship between them forming a net of reciprocal communication, called functional resting state network (RSN). Smith et al. in 2009 [2] identified 10 RSNs in fMRI data acquired from a healthy population that are now commonly used in the nomenclature of RSNs and as reference to manually identify them on fMRI new data: medial visual area (MVA), occipital visual area (OVA), lateral visual area (LVA), default mode network (DMN), cerebellum (CER), auditory cortices (AUD), sensory-motor area (SMA), executive control (EXE), frontoparietal area left (FPA-l), and frontoparietal area right (FPA-r). Resting-state fMRI studies provide valuable information on the brain's intrinsic connectivity and organization. FC is assumed to be supported by structural connectivity.

Brain structural connectivity refers to the physical connections between different regions of the brain, typically represented by white matter tracts composed of axonal fibers. The interhemispheric FC refers to the coordinated activity between homologous regions in the left and right hemispheres of the brain. It is assumed to be specifically supported by the corpus callosum (CC), the brain's largest white matter structure that promotes the transfer of information between the two hemispheres ensuring that the two hemispheres can process and integrate information simultaneously. Therefore, CC is considered the primary structure responsible for the symmetry with respect to the midline observed in many RSNs [3, 4]. RSNs such as FPA-l and FPA-r are characterized by

The research has received funding from the project "PR Marche Fondo Sociale Europeo Plus 2021/2027"

spatial maps that are almost entirely unilateral, so interhemispheric FC cannot be assessed from them [3].

An effective approach to understanding the role of CC is to compare brain FC in individuals with an intact CC and those without it. Therefore, some studies assessed FC after surgical resection of CC in patients with medically refractory epilepsy. In this context, callosotomized patients (also named "split-brain" patients), *i.e.*, patients who underwent surgical resection of CC for epileptic therapeutic reasons, represent the appropriate population to test whether the role of CC should be downsized to one of the possible structural modalities used by the brain to ensure interhemispheric FC. The results of these studies are sometimes controversial because in some cases the CC section significantly reduced interhemispheric FC, while in others it appears to be maintained, at least for some RSNs. This evidence leads to the hypothesis that in some callosotomized patients, depending upon the patient's age at the time of CC resection and the extent and localization of CC resection, if partial, some RSNs retain bilaterality; this residual connectivity would suggest the involvement of alternative pathways, possibly of subcortical origin, in their post-surgical arrangement [4-6]. O'Reilly et al. [7] suggested that, at least in non-human Primates, RSN integrity and bilaterality could be supported by indirect anatomical pathways in the absence of CC. Nomi et al. [8] observed differences in cerebellar white matter and consequently formulated the hypothesis of a compensatory cerebellar role for the FC post-surgery reorganization. Neuroplasticity plays a key role in the brain ability to reorganize pathways and modes of communication, forming new ones or strengthening existing ones.

The aim of the study is to analyze cerebello-cortical FC, *i.e.*, the FC between cerebellum and cortical RSNs, as well as intra-cerebellar FC, in a totally callosotomized patient and in a healthy control for comparison. Possible differences could indirectly evidence the role of cerebellum in making up for the absence of the CC. The study has to be intended as a pilot one, paving the way, based on the results obtained, for a larger investigation involving a wider population. Such an analysis would offer objective insights into the role of the cerebellum in maintaining interhemispheric connectivity following CC resection, thereby contributing to our understanding of the brain's capacity for cortical reorganization.

II. Materials and Methods

A. Study subjects

The study individuals consisted of one patient and one subject, referred to as P2 and S1, respectively, in accordance with the alphanumeric identifier used in [4]. P2 was a drug-resistant epileptic patient who underwent total callosotomy, while S1 was healthy and used as control. At the time of data acquisition, P2 was a 53-year-old man and had undergone two CC resections resulting in total resection, the first around age 20 and the second around age 30. On the other side, S1 was a 31-year-old woman. Informed consent was obtained by all participants who assented to be enrolled in the experimental procedure, which was approved by the ethical committee of Università Politecnica delle Marche [4].

B. Acquisition protocol and magnetic resonance images

Anatomical and functional MRI images were acquired in resting conditions using a Signa HDxt 1.5T GE Medical System MRI scanner. The T1-weighted anatomical images resulted from MPRAGE sequence. The functional images (acquired in ascending order) resulted from an echo planar image (EPI) gradient-echo sequence. Anatomical and functional image settings are reported in Table I. During the acquisition protocol, lasting about 8 minutes for the anatomical images and 15 minutes for the functional ones, subjects were asked to remain as still as possible inside the MRI machine, keeping their eyes open while relaxing [4].

C. Preprocessing and parcellation

The anatomical and functional magnetic resonance images of P2 and S1 were analyzed using CONN, a MATLAB/SPM-based toolbox [9]. The preprocessing pipeline applied was the standard one proposed by the toolbox, which includes: (1) co-registration through a 6-parameter transformation with correction of susceptibility distortion interactions; (2) slice timing correction, considering the mid-acquisition time as reference, and outlier detection and exclusion; (3) segmentation into the three principal tissues (*i.e.*, white matter, grey matter and cerebrospinal fluid); (4) normalization with respect to the standard Montreal Neurological Institute (MNI) template; (5) spatial smoothing using a Gaussian kernel of 5 mm full width half maximum (FWHM) for the spatial convolution [10]. Functional images were also denoised by regressing out potential confounding factors, for example derived from white matter, cerebrospinal fluid, motions, or outlier scans. In addition, BOLD signals were band-passed between 0.008 Hz and 0.09 Hz.

After that, brain and cerebellar parcellation were performed. Specifically, the brain was parcellated into 30 RSN regions of interest (ROIs) derived from the Human Connectome Project (HCP)-ICA networks, and the cerebellum was parcellated into 18 cerebellar ROIs defined according to the Automated Anatomical Labelling (AAL) atlas, and here numbered as reported in Table II.

D. Functional connectivity analysis

The correlation of each cerebellar ROI to all the considered ROIs (*i.e.*, the other 17 cerebellar ROIs and the 30 RSN ROIs) was then evaluated by computing the Fisher z-transformed bivariate correlation coefficients [11]. More specifically, the mean BOLD time series was extracted within the voxels of each ROI to estimate ROI-to-ROI connectivity (RRC) matrices. RRC matrices of P2 and S1 were subtracted and compared using the Wilcoxon signed rank test per cerebellar ROI. Statistical significance (p) was set to 0.05 in all cases.

TABLE I. Anatomical and Functional MRI Image Setting

Parameters	Anatomical	Functional
echo time (TE)	6.7 ms	50 ms
repetition time (TR)	14.7 s	3 s
flip angle	15°	90°
field of view (FOV)	290x290 mm	192x192 mm
matrix size	512x512	64x64
number of volumes	not applicable	300
number of slices	158 (sagittal)	35 (axial)
slice thickness	1 mm	4 mm
gap between slices	0 mm	0 mm
voxel resolution	1×0.5664×0.5664 mm	3×3×4 mm

TABLE II. NUMBERING OF RSN AND CEREBELLAR ROIS

RSN ROIs									
1	Default Mode MPFC	7	Sensorimotor Superior	13	Salience Anterior Ins L	19	Dorsal Attention FEF L	25	Frontoparietal LPFC R
2	Default Mode LP L	8	Visual Medial	14	Salience Anterior Ins R	20	Dorsal Attention FEF R	26	Frontoparietal PPC R
3	Default Mode LP R	9	Visual Occipital	15	Salience RPFC L	21	Dorsal Attention IPS L	27	Language IFG L
4	Default Mode PCC	10	Visual Lateral L	16	Salience RPFC R	22	Dorsal Attention IPS R	28	Language IFG R
5	Sensorimotor Lateral L	11	Visual Lateral R	17	Salience SMG L	23	Frontoparietal LPFC L	29	Language pSTG L
6	Sensorimotor Lateral R	12	Salience ACC	18	Salience SMG R	24	Frontoparietal PPC L	30	Language pSTG R
Cerebellar ROIs									
1	Cerebellum Crus 1 L	5	Cerebellum 3 L	9	Cerebellum 6 L	13	Cerebellum 8 L	17	Cerebellum 10 L
2	Cerebellum Crus 1 R	6	Cerebellum 3 R	10	Cerebellum 6 R	14	Cerebellum 8 R	18	Cerebellum 10 R
3	Cerebellum Crus 2 L	7	Cerebellum 45 L	11	Cerebellum 7b L	15	Cerebellum 9 L		
4	Cerebellum Crus 2 R	8	Cerebellum 45 R	12	Cerebellum 7b R	16	Cerebellum 9 R		

ACC, anterior cingulate cortex; FEF, frontal eye field; IFG, inferior frontal gyrus; Ins, insula; IPS, intraparietal sulcus; L, left; LP, lateral parietal; LPFC, lateral prefrontal cortex; MPFC, medial prefrontal cortex; PCC, posterior cingulate cortex; R, right; RPFC, rostral prefrontal cortex; SMG, supramarginal gyrus; pSTG, posterior superior temporal gyrus.

E. Seed-based connectivity analysis

Seed-based connectivity (SBC) maps were estimated to characterize the spatial pattern of FC with the pre-defined seeds [11], which were each of the 18 cerebellar ROIs. Maps resulted from the estimation of FC strength between each seed cerebellar ROI and the target voxel. This strength was computed by Fisher-transformed bivariate correlation coefficients from a weighted general linear model. Fisher transformation allowed normalization of the Pearson correlation coefficients resulting in a stable variance and a better statistical inference. Regions within the obtained SBC maps that exhibited strong correlations were identified by three-dimensional visual inspection and subsequently mapped onto the RSNs outlined by Smith et al. (excluding FPA-r, FPA-l, and CER).

III. RESULTS

RRC results revealed distinct patterns of FC between P2 and S1, both within the cerebellum (*i.e.*, intra-cerebellar connectivity) and between cerebellar ROIs and RSN ROIs (*i.e.*, cerebello-cortical connectivity), as shown in Fig. 1 and Fig. 2. Specifically, Fig. 1 illustrates cerebello-cortical connectivity correlations, while Fig. 2 illustrates intra-cerebellar connectivity correlations. In both figures, panel A shows the RRC matrix of P2, panel B shows the RRC matrix of S1, and panel C shows the RRC matrix of the difference between the two (P2-S1).

Cerebellar connectivity correlations with RSN ROIs were found to be statistically significant in 47% of cases for P2 and 37% for S1 (Fig. 1, panels A and B). Concerning intra-cerebellar connectivity correlations, 18% and 33% were

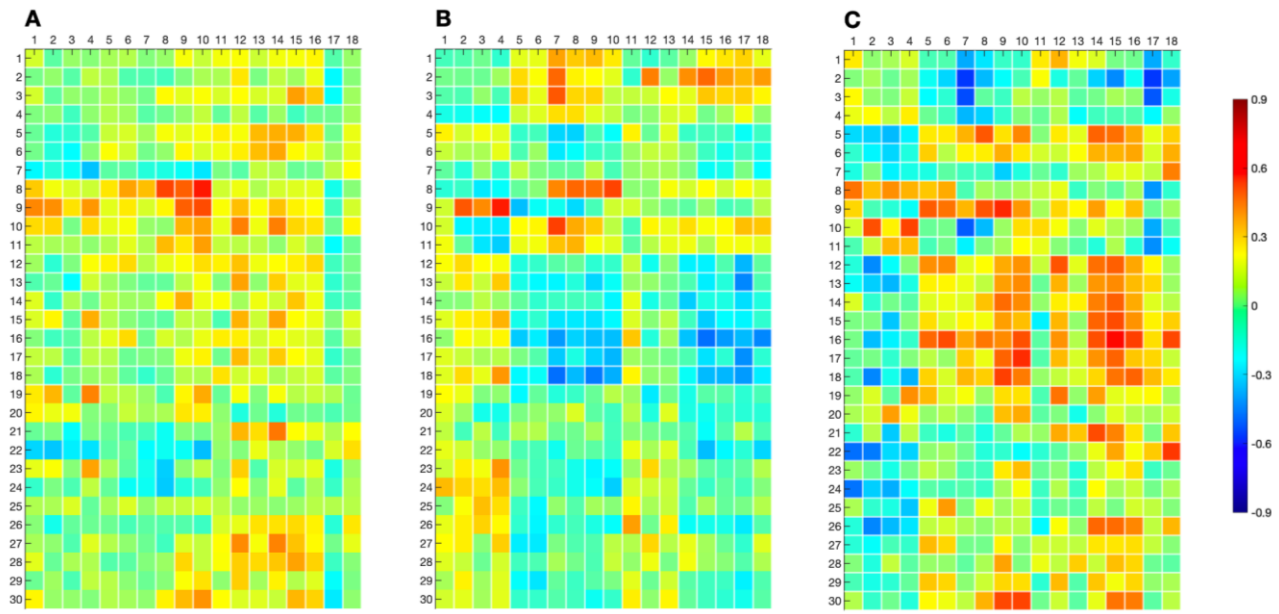

Fig. 1. ROI-to-ROI connectivity (RRC) matrices describing cerebello-cortical connectivity for P2 and S1. (*Panel A refers to P2, panel B refers to S1, and panel C refers to P2-S1 difference. RRC matrices show the pairwise connectivity between the 18 cerebellar ROIs (horizontal axis) and the 30 RSN ROIs (vertical axis), with each element corresponding to the value of the Fisher z-transformed correlation coefficient. The color of each element represents the level of FC according to the color bar shown on the right of the figure: toward-blue colors represent negative correlations and toward-red colors represent positive correlations, ranging from −0.9 to 0.9*).

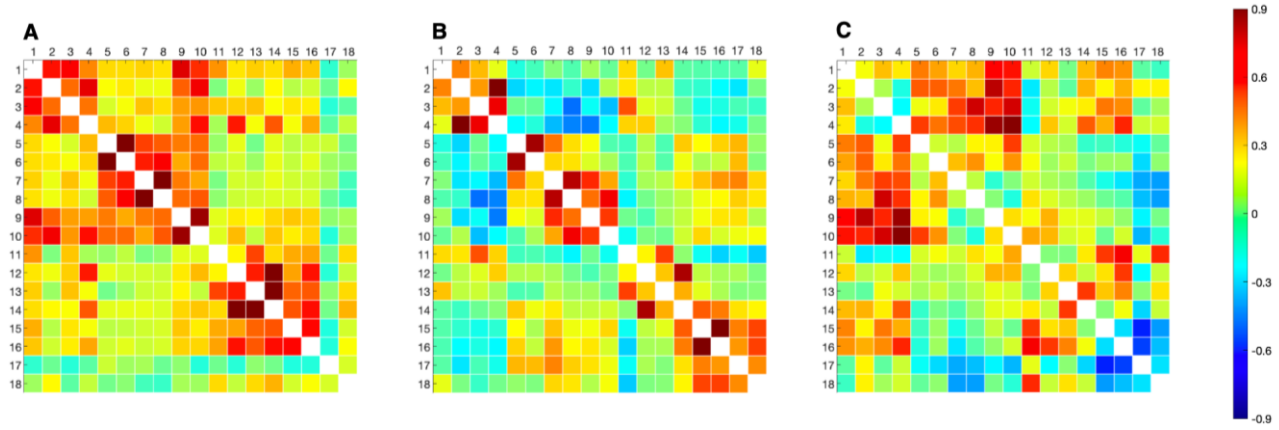

Fig. 2. ROI-to-ROI connectivity (RRC) matrices describing intra-cerebellar connectivity for P2 and S1. (*Panel A refers to P2, panel B refers to S1, and panel C refers to P2-S1 difference. RRC matrices show the pairwise connectivity between 18 cerebellar ROIs, with each element corresponding to the value of the Fisher z-transformed correlation coefficient. The color of each element represents the level of FC according to the color bar shown on the right of the figure: toward-blue colors represent negative correlations and toward-red colors represent positive correlations, ranging from −0.9 to 0.9*).

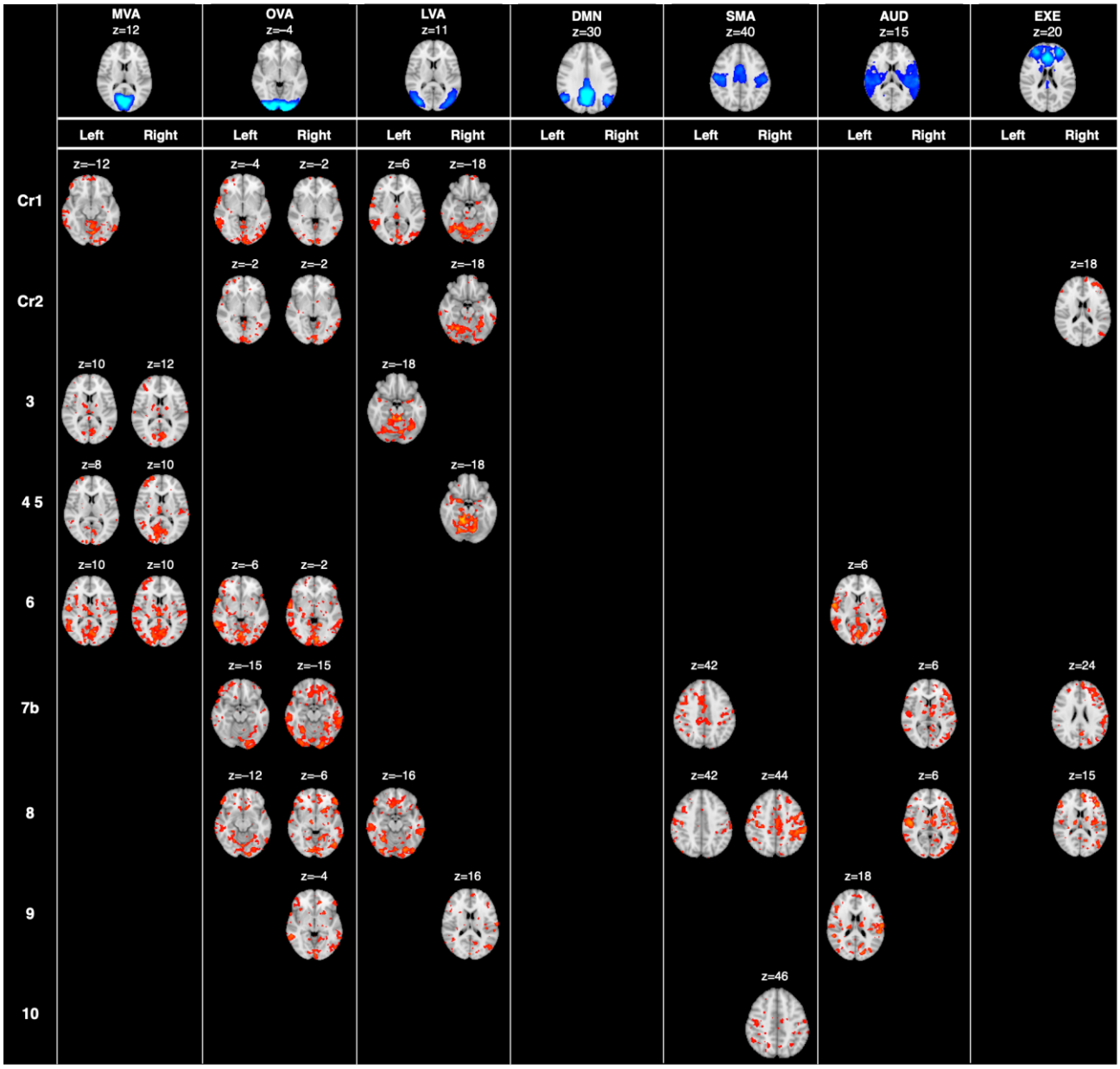

Fig. 3. Seed-based connectivity (SBC) of cerebellar ROIs for P2. *(Numbers displayed at the top of each brain figurine indicate the z-coordinate in the MNI space. When two brain figurines are shown, the left and right ones indicate the FC of cerebral cortex with the left and right cerebellar ROIs, respectively. According to the radiological convention, the left hemisphere is on the right. Cr1=Crus 1; Cr2=Crus 2).*

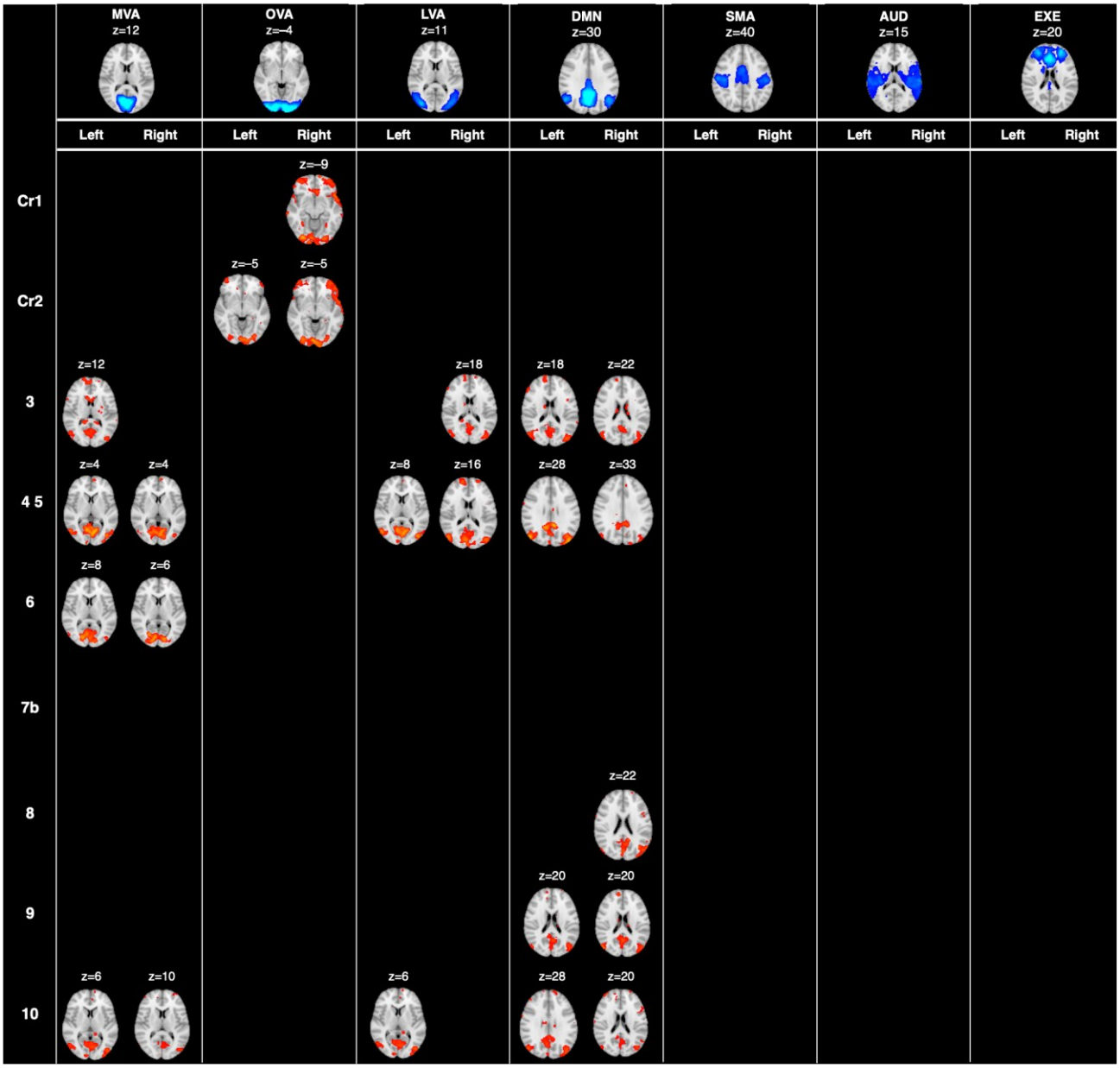

Fig. 4. Seed-based connectivity (SBC) of cerebellar ROIs for S1. *(Numbers displayed at the top of each brain figurine indicate the z-coordinate in the MNI space. When two brain figurines are shown, the left and right ones indicates the FC of cerebral cortex with the left and right cerebellar ROIs, respectively. According to the radiological convention, the left hemisphere is on the right. Cr1=Crus 1; Cr2=Crus 2).*

statistically significant for P2 and S1, respectively (Fig. 2, panels A and B). Moreover, FC correlations between cerebellum and RSN ROIs were statistically different between P2 and S1 in 11 cerebellar ROIs, 7 of which were on the right side of the cerebellum and 4 on the left. A statistically significant difference was also found for intra-cerebellar FC correlations, generally higher in P2 than in S1.

Differences in cerebello-cortical FC are confirmed by the results of the SBC analysis presented in Fig. 3 and Fig. 4. The plots display axial slices of the brain MNI template overlaid with the statistical maps resulting from SBC analysis, highlighting voxels (defining clusters if adjacent) corresponding to BOLD signal having significant positive correlation with the BOLD signal pertaining to the 18 cerebellar ROIs, where in the figure, they are arranged in rows as pairs of homologous areas. To facilitate the identification of correspondence between the clusters and Smith's RSNs, the latter are displayed at the top.

For P2 (Fig. 3), the significant clusters vary by cerebellar seed and include especially the visual RSNs (*i.e.*, MVA, OVA, LVA), SMA, AUD and EXE, indicating the functional connectivity of these RSNs with cerebellar ROIs. Similarly, for S1 (Fig. 4), the clusters vary by cerebellar seed, but unlike the patient, they mainly include, in addition to visual RSNs (*i.e.*, MVA, OVA, LVA), DMNs and not SMA, nor AUD, nor EXE.

IV. Discussion

This study analyzed cerebello-cortical and intra-cerebellar FC in a totally callosotomized patient and in a healthy control for comparison, in order to highlight possible differences that could indirectly disclose the role of cerebellum in balancing the absence of the CC. The present research follows a previous one demonstrating a residual interhemispheric FC, mainly in sensory networks, in case of total resection of the CC [4].

The mechanism explaining the residual interhemispheric FC is likely underpinned by subcortical pathways, possibly supported by a thalamic contribution, or by a cerebellar contribution, or by a combination of the two. In the previous research [4], an SBC analysis was performed placing two seeds in the right and left thalamus separately, evidencing a thalamic contribution to connectivity with contralateral cortical regions, in particular the auditory ones [4].

The present study offer objective deeper insights into the cerebellum role, as an additional or alternative possible pathways supporting the residual interhemispheric connectivity previously observed after CC resection. The results from RRC (Fig. 1) indicate higher positive correlations between cerebellum and RSNs in the split-brain patient with respect to the healthy control. In particular, the highest differences between RRC matrices (Fig. 1, panel C) were observed in relation to the SMA (rows 5 and 6 of the RRC matrix), EXE (rows 12-18 of the RRC matrix), MVA (row 8 of the RRC matrix) and OVA (row 9 of the RRC matrix). This was confirmed by the SBC analysis (Fig. 3-4), which assessed the correlation of each cerebellar ROI with every cortical voxel. Voxels showing the strongest correlations with cerebellar seeds identified regions matching primarily Smith's MVA, OVA, AUD and SMA. This is in line with the studies by Roland et al. [12] and Stark et al. [13], who found residual interhemispheric FC after callosotomy in the sensorimotor and vision networks. Results from RRC analysis (Fig. 2) pointed out a higher intra-cerebellar processing in the split-brain patient than in the healthy control. Moreover, a strong correlation was primarily observed between left-right homologous cerebellar ROIs in the healthy control, while in the split-brain patient a more diffused high connectivity was observed, possibly suggesting the integration and/or transmission of a greater flow of information by the cerebellum.

The finding of cerebellar connectivity agrees with the previous observations of the study by Marcantoni et al. [4]. Analyzing the RSNs in the same split-brain patient considered here, it was previously reported that bilateral FC still persists between the right and left regions in the SMA, primary sensory cortices (*i.e.*, OVA and AUD, with predominant activation in the right hemisphere in the latter case), and MVA; other networks, as LVA and DMN, displayed bilateral activation, although highly predominant in one hemisphere (more than OVA and AUD). Therefore, bilateral activation of these RSNs could likely be mediated by the cerebellum.

Thus, the outcomes of the RRC and SBC analysis performed here support the general hypothesis that this spatial correspondence may indicate a coordination that is subcortical in origin. In this study, we have focused on cerebellum involvement, but further investigations should consider other subcortical structures. In addition, this study proposes a pipeline to analyze the possible mediators of cortical connectivity considering fMRI images only. The same pipeline can be generalized and used in future studies to evaluate the role of other subcortical structures in facilitating and modulating communications between the two hemispheres, providing an objective way for understanding compensatory neural mechanisms, particularly in conditions where direct cortical pathways, such as the CC, are disrupted.

However, some limitations should be acknowledged. First, the present findings, obtained from one patient and one healthy control only, should be framed as descriptive observations. Second, age and gender differences between the patient (53 years, male) and the healthy control (31 years, female) could influence resting-state connectivity and partially account for the observed deviations. However, recent studies do not show significant differences in FC among thirties and fifties people [14]; a certain degree of gender difference was shown in a recent study describing higher FC in females than males in the left hemisphere, including connections to the somatomotor and DMN, and lower FC symmetrically distributed between the two hemispheres [15].

V. Conclusions

This pilot study provides useful insights into the possible role of the cerebellum in maintaining and reorganizing interhemispheric FC in the case of total resection of CC. The evidence provided strongly suggests a contribution of a cerebello-cortical loop in the maintenance and reorganization of interhemispheric FC in the split-brain patient analyzed.

References

[1] K. A. Smitha et al., "Resting state fMRI: a review on methods in resting state connectivity analysis and resting state networks," Neuroradiol. J. vol. 30, pp. 305–317, 2017.

[2] S. M. Smith et al., "Correspondence of the brain's functional architecture during activation and rest," Proc. Natl. Acad. Sci. USA vol. 106, pp. 13040–13045, 2009.

[3] J. P. Owen et al., "Resting-State Networks and the Functional Connectome of the Human Brain in Agenesis of the Corpus Callosum," Brain Connect., vol. 3, pp. 547-562, 2013.

[4] I. Marcantoni et al., "Interhemispheric functional connectivity: an fMRI study in callosotomized patients," Front. Hum. Neurosci., vol. 18, 1363098, 2024.

[5] L. Mancuso, L. Q. Uddin, A. Nani, T Costa, F. Cauda, "Brain functional connectivity in individuals with callosotomy and agenesis of the corpus callosum: A systematic review," Neuroscience and biobehavioral reviews, vol. 105, pp. 231–248, 2019.

[6] L. Q. Uddin et al. "Residual functional connectivity in the split-brain revealed with resting-state functional MRI," Neuroreport. Vol. 19, pp. 703-709, 2008.

[7] J. X. O'Reilly et al. "Causal effect of disconnection lesions on interhemispheric functional connectivity in rhesus monkeys," Proc. Natl. Acad. Sci. U.S.A. Vol. 110, pp. 13982–13987, 2013.

[8] J. S. Nomi et al., "Diffusion weighted imaging evidence of extra-callosal pathways for interhemispheric communication after complete commissurotomy," Brain Struct. Funct., vol. 224, pp. 1897–1909, 2019.

[9] A. Nieto-Castanon, and S. Whitfield-Gabrieli, CONN functional connectivity toolbox: RRID SCR_009550, release 22. Boston, MA: Hilbert Press, 2022.

[10] A. Nieto-Castanon, "FMRI minimal preprocessing pipeline" in Handbook of functional connectivity magnetic resonance imaging methods in CONN, Boston, MA: Hilbert Press, pp. 3–16, 2020.

[11] A. Nieto-Castanon, "Functional connectivity measures" in Handbook of functional connectivity magnetic resonance imaging methods in CONN, Boston, MA: Hilbert Press, 26–62, 2020

[12] J. L. Roland et al., "On the role of the corpus callosum in interhemispheric functional connectivity in humans," Proc. Natl. Acad. Sci. U.S.A. vol. 114, pp. 13278-13283, 2017.

[13] D. E. Stark et al., "Regional variation in interhemispheric coordination of intrinsic hemodynamic fluctuations," J Neurosci, vol. 28, pp. 13754–1376, 2008.

[14] M. Khalilian et al., "Age-related differences in structural and resting-state functional," Aging Brain, vol. 5,100105, 2024.

[15] Kang et al., "Sex differences in structural and functional connectivity in healthy young adults from the Amsterdam Open MRI Collection". Brain Structure and Function, vol. 230, 98, 2025.