

Pregnancy 3 months after inclisiran injection: a unique case report including newborn baby monitoring

Massimiliano Allevi^{1,2}, Matteo Landolfo^{1,3}, Federico Giulietti³,
Francesco Spannella ^{1,3*}, and Riccardo Sarzani^{1,3}

¹Department of Clinical and Molecular Sciences, University 'Politecnica delle Marche', 60020 Ancona, Italy; ²Unit of Post-Acute Care, IRCCS INRCA, 60127 Ancona, Italy; and ³Internal Medicine and Geriatrics, 'Hypertension Excellence Centre' of the European Society of Hypertension, Società Italiana per lo Studio dell'Aterosclerosi (SISA) LIPIGEN Centre, IRCCS INRCA, 60127 Ancona, Italy

Received 6 September 2024; revised 2 December 2024; accepted 30 January 2025; online publish-ahead-of-print 21 February 2025

Background

Data on the safety of inclisiran, a lipid-lowering small interfering RNA (siRNA) inhibiting proprotein convertase subtilisin/kexin type 9 (PCSK9) secretion, during pregnancy are absent.

Case summary

A 30-year-old woman suffering from heterozygous familial hypercholesterolaemia started treatment with inclisiran 25 weeks before the start of gestation and received a second administration 13 weeks before the start of gestation. As soon as we became aware of the unplanned pregnancy, given the absence of any data regarding the administration of inclisiran during this period, the treatment was discontinued and the pregnancy was closely monitored. After a normal and full-term gestation, birth occurred at 41 + 0 gestational weeks. The baby was female and healthy, with normal anthropometry for her gestational age; her growth and development in the first 8 months of life followed a normal course.

Discussion

Potential harms to the foetus with systemic malformations have been highlighted with the genetically proxied LDL cholesterol lowering through PCSK9. To the best of our knowledge, this is the first case of pregnancy initiated few months after inclisiran administration, without reporting any adverse effect on the patient or the baby. More data are needed on the pharmacodynamics and safety of siRNAs in general, and of inclisiran in particular, to confirm that this drug could be safe even in this specific setting.

Keywords

Inclisiran • Pregnancy • PCSK9 inhibitor • Familial hypercholesterolaemia • Case report

ESC curriculum

8.3 Dyslipidaemia • 8.5 Primary prevention • 9.8 Pregnancy with cardiac symptoms or disease

Learning points

- To date, no data regarding therapy with inclisiran during pregnancy are available.
- This case report describes a pregnancy started 13 weeks after the administration of inclisiran, reporting no adverse events both in the pregnant patient and in the foetus, with regular growth and development.
- This is the first case of pregnancy initiated a few months after inclisiran administration.

* Corresponding author. Tel: +39 071 5964595, Fax: +39 071 889232, Email: f.spannella@univpm.it

Handling Editor: David Oxborough

Peer-reviewers: Marie-Luise Dikour; Stefania Angela Di Fusco

Compliance Editor: Deepti Ranganathan

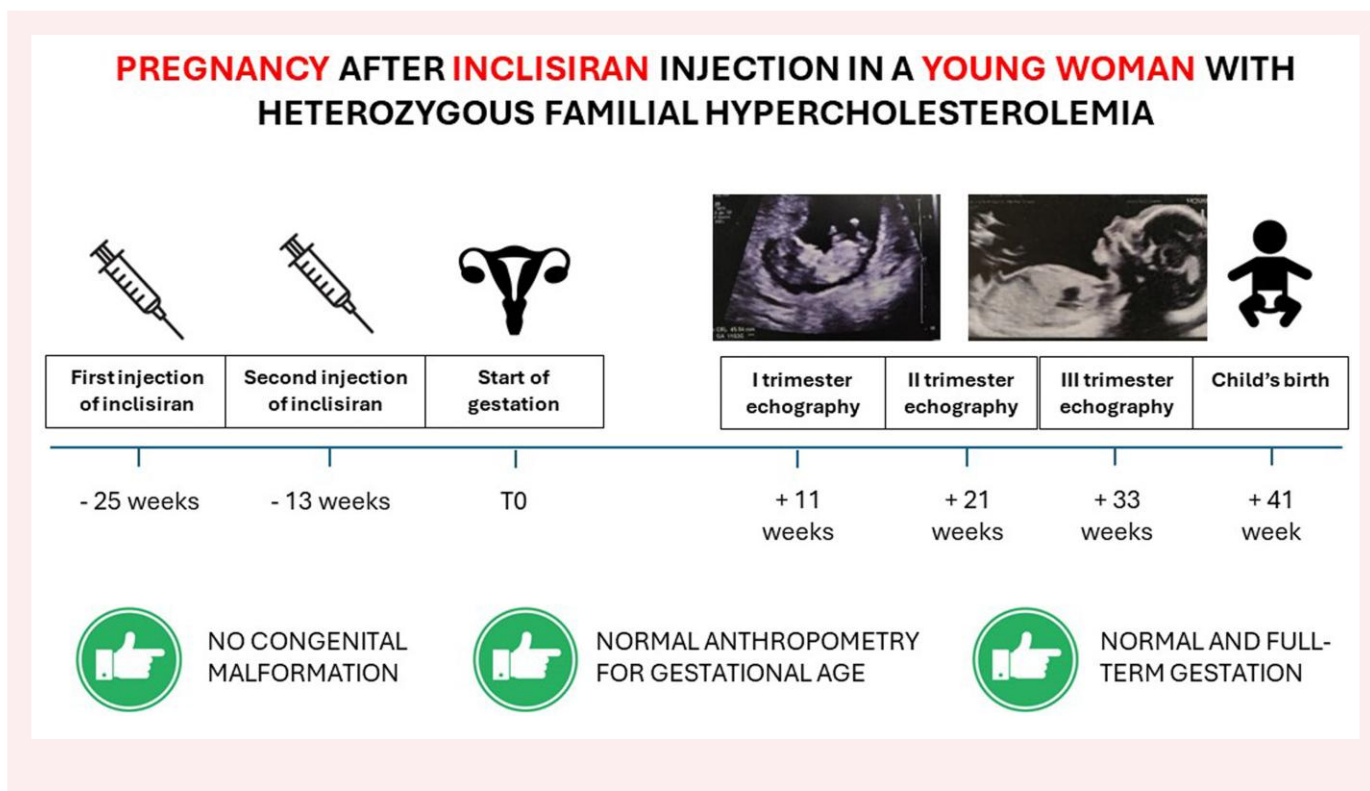
© The Author(s) 2025. Published by Oxford University Press on behalf of the European Society of Cardiology.

This is an Open Access article distributed under the terms of the Creative Commons Attribution-NonCommercial License (<https://creativecommons.org/licenses/by-nc/4.0/>), which permits non-commercial re-use, distribution, and reproduction in any medium, provided the original work is properly cited. For commercial re-use, please contact reprints@oup.com for reprints and translation rights for reprints. All other permissions can be obtained through our RightsLink service via the Permissions link on the article page on our site—for further information please contact journals.permissions@oup.com.

Introduction

Proprotein convertase subtilisin/kexin type 9 (PCSK9) inhibition is a valuable option for the treatment of high LDL cholesterol (LDL-C) levels, both in primary and secondary prevention, when conventional therapies (high-intensity statins plus ezetimibe) are not able to achieve LDL-C goal according to the patient's cardiovascular (CV) risk.¹ Inclisiran is a small interfering RNA (siRNA) specifically designed to hamper hepatic PCSK9 production. Administered subcutaneously twice yearly,² it has been demonstrated to significantly reduce LDL-C with a reassuring safety profile.³ Cholesterol is critical in placentation and early embryonic development,⁴ and PCSK9 plays a pivotal role in its regulation.⁵ Studies on genetic polymorphisms have described an association between lower PCSK9 levels and neural tube defects.⁶ Despite the lack of clinical data, manufacturers advise against PCSK9 inhibition during pregnancy, and it has been proved that both monoclonal antibodies (mAbs) and siRNAs cross the placenta. A recent study,⁷ using drug target Mendelian randomization, has corroborated current warnings against PCSK9 inhibition in pregnancy. To date, no LDL-C-lowering therapies, except for bile acid sequestrants, are approved for use during pregnancy. Therefore, no data regarding the administration of inclisiran during pregnancy are currently available.⁸

Summary figure



Case presentation

A 30-year-old woman with heterozygous familial hypercholesterolemia (HeFH) (basal LDL-C of 364 mg/dL, Dutch Lipid Clinic Network Score 15), genetically confirmed by loss-of-function variant affecting an allele of the gene coding for LDL-R [c.1374_375del AG (exon 10) p.Arg458Serfs*8 Null allele], developed a painful and

relapsing injection site reaction to both alirocumab and evolocumab, two fully human mAbs directed against PCSK9.⁹ Therefore, treatment was shifted to inclisiran as soon as it became available in clinical practice. The patient had no other known diseases in her past medical history. At 25 weeks before the start of gestation, the first administration of inclisiran was given, followed by the second after 3 months (13 weeks before the start of gestation), in both cases without adverse events. Variations of LDL-C values according to lipid-lowering therapy are reported in [Table 1](#). The patient had an unplanned pregnancy 13 weeks after the second administration of inclisiran. As soon as the pregnancy was diagnosed, the patient was advised to discontinue lipid-lowering treatment with rosuvastatin 40 mg and ezetimibe 10 mg, and the scheduled administration of inclisiran was cancelled.

To date, this is the first documented case of pregnancy initiated after inclisiran injection. Consequently, the gestation was closely monitored throughout its duration, and the health of both the mother and the newborn child have been assessed in the first months after delivery. The patient decided not to interrupt the pregnancy, which proceeded without complications, except for mild gestational hypothyroidism. Since the first weeks and throughout the entire pregnancy, the patient took multivitamin supplements, also containing folic acid (400 µg) to minimize the risk of neural tube defects, according to good clinical practice. Prenatal ultrasound was performed at the first, second, and third trimesters of pregnancy, always with normal findings ([Table 2](#)). After a normal and full-term gestation, birth occurred at 41 + 0 gestational

weeks. Delivery was vaginal, eutocic, and without complications. The baby was female and healthy, with standard anthropometry for her gestational age. Specifically, her length was 48.5 cm (18th percentile), her weight was 3.06 kg (22nd percentile), and her head circumference was 35 cm. The Apgar score was 9 at 1 min and 10 at 5 and 10 min.

The baby's growth and development in her first months followed a regular course; her monthly anthropometric data are summarized in [Table 3](#).

Table 1 Changes in mother's LDL-C values according to modification of lipid-lowering therapy

	LDL-C (mg/dL)
No lipid-lowering therapy at HeFH diagnosis (44 weeks before the start of gestation)	364
High-intensity statin plus ezetimibe (25 weeks before the start of gestation)	191
Three months after the first injection of inclisiran (13 weeks before the start of gestation)	103
No lipid-lowering therapy (soon after the child's birth)	391
Three months after the complete resumption of lipid-lowering treatment (8 months after the child's birth)	75

LDL-C, LDL cholesterol; HeFH, heterozygous familial hypercholesterolaemia.

Table 2 Anthropometry of the foetus during gestation, second and third trimesters

	BPD (mm)	HC (mm)	AC (mm)	FL (mm)	HL (mm)
Second trimester	46.1 (25–50th %ile)	176.1 (50–75th %ile)	146.6 (50–75th %ile)	31.1 (25–50th %ile)	30.4 (25–50th %ile)
Third trimester	80.5 (75–90th %ile)	302.0 (50–75th %ile)	273.0 (95th %ile)	62.2 (90–95th %ile)	54.4 (75–90th %ile)

BPD, biparietal diameter; HC, head circumference; AC, abdominal circumference; FL, femoral length; HL, humeral length; %ile, percentile.

Table 3 Anthropometry of the newborn baby at birth and after 1, 2, 3, 6, and 8 months

	Length (cm)	Weight (kg)	BMI (kg/m ²)	Head circumference (cm)
At birth	48.5 (18th %ile)	3.06 (22nd %ile)	13.0	35.0 (50–75th %ile)
1 month	53.0 (10–25th %ile)	4.00 (25–50th %ile)	14.2	37.2 (25–50th %ile)
2 months	56.0 (25–50th %ile)	5.35 (75–90th %ile)	17.1	39.3 (50–75th %ile)
3 months	60.5 (50–75th %ile)	6.30 (75–90th %ile)	17.2	40.7 (50–75th %ile)
6 months	65 (50–75th %ile)	7.6 (50–75th %ile)	17.99	42.8 (50–75th %ile)
8 months	69 (25–50th %ile)	7.8 (10–25th %ile)	16.38	44 (25–50th %ile)

BMI, body mass index; %ile, percentile.

During the last available measurement, when the baby was 8 months and 23 days old, a slight decline in her growth emerged: length was 69 cm (25–50th percentile, with mother of short stature), weight was 7.8 kg (10–25th percentile) with a body mass index (BMI) of 16.38, and head circumference was 44 cm (25–50th percentile). The gynaecologist attributed this deflection to a progressive reduction and early cessation of breastfeeding from the fourth to the sixth month after delivery, due to low milk supply and a late replacement with formula feeding during the weaning. On the other hand, breastfeeding cessation allowed the patient to resume lipid-lowering treatment with rosuvastatin 40 mg, ezetimibe 10 mg, and inclisiran. The siRNA administration was resumed 6 months after delivery, followed by a second administration 3 months later. Variations in the mother's LDL-C values according to the modification of therapy are summarized in [Table 1](#).

Discussion

To the best of our knowledge, this is the first case of pregnancy initiated few months after inclisiran administration. Clinical trials evaluating the safety of PCSK9 inhibition during pregnancy are not practicable due to ethical concerns. To fill this lack of data, a recent study⁷ has used drug target Mendelian randomization to test the safety of PCSK9-inhibiting drugs. It has evaluated the association of PCSK9 circulating levels and PCSK9 gene expression in the liver with

congenital malformations. Genetic association estimates were extracted from genome-wide association study summary data for LDL on 1 320 016 individuals. Genetically proxied LDL-C lowering through PCSK9 resulted in higher odds of malformations affecting multiple systems, such as the VACTERL association (vertebral defects, anal atresia, cardiac defects, tracheo-oesophageal fistula, renal and limb abnormalities).

There are no available data regarding inclisiran use in pregnancy, so we suspended treatment as soon as pregnancy was reported. Inclisiran is no longer detectable in the circulation 48 h after administration, given its highly selective hepatic uptake,¹⁰ so we can reasonably assume there was no circulating drug at conception and during gestation. However, its effect on circulating PCSK9 levels and LDL-C was maintained at conception and during pregnancy in its first months. We monitored the progression of gestation and the development of the foetus in a non-invasive way. The observation and choice of interventions were limited by the lack of available clinical experience in cases of a similar nature. In this case report on a pregnancy started 13 weeks after the administration of inclisiran, no adverse events occurred to both the patient and the foetus, and subsequently the newborn child, with regular growth and development. This case report has some limitations. First, the LDL-C levels of the baby are currently not available. Second, further data from a longer follow-up need to be collected, but are still not available at present, due to the age of the baby (nearly 11 months old).

More solid data are needed regarding the pharmacodynamics and safety of siRNAs in general, and of inclisiran in particular, to confirm that these drugs could be safe in this specific setting. A viable therapeutic option is desirable for fertile women who are willing to become pregnant, but are at higher CV risk, such as those suffering from FH, for whom the benefits of lipid-lowering treatment may outweigh the risks.⁸

Lead author biography



Massimiliano Allevi is a medical doctor from Italy (University 'Politecnica delle Marche'). He is a specialist in geriatrics and attended the 'Hypertension Excellence Centre' of the European Society of Hypertension in Ancona, mainly dealing with dyslipidaemia and familial hypercholesterolaemia.

Acknowledgements

Unconditional support for article publication charges was provided by Novartis Farma Italy.

Conflict of interest: None declared.

Funding: This research was supported by 'Politecnica delle Marche' University ("Ricerca di Ateneo 2024" to Riccardo Sarzani).

Data availability

The data underlying this article are available in the article. All data are incorporated into the article.

References

1. Mach F, Baigent C, Catapano AL, Koskinas KC, Casula M, Badimon L, et al. 2019 ESC/EAS guidelines for the management of dyslipidaemias: lipid modification to reduce cardiovascular risk. *Eur Heart J* 2020;**41**:111–188.
2. Raal FJ, Kallend D, Ray KK, Turner T, Koenig W, Wright RS, et al. Inclisiran for the treatment of heterozygous familial hypercholesterolemia. *N Engl J Med* 2020;**382**:1520–1530.
3. Sarzani R, Spannella F, Di Pentima C, Giulietti F, Landolfo M, Allevi M. Molecular therapies in cardiovascular diseases: small interfering RNA in atherosclerosis, heart failure, and hypertension. *Int J Mol Sci* 2023;**25**:328.
4. Porter FD. Human malformation syndromes due to inborn errors of cholesterol synthesis. *Curr Opin Pediatr* 2003;**15**:607–613.
5. Pecks U, Rath W, Maass N, Berger B, Lueg I, Farrokh A, et al. Fetal gender and gestational age differentially affect PCSK9 levels in intrauterine growth restriction. *Lipids Health Dis* 2016;**15**:193.
6. Jerome RN, Pulley JM, Roden DM, Shirey-Rice JK, Bastarache LA, R Bernard G, et al. Using human 'experiments of nature' to predict drug safety issues: an example with PCSK9 inhibitors. *Drug Saf* 2018;**41**:303–311.
7. Ardissino M, Slob EAW, Reddy RK, Morley AP, Schuermans A, Hill P, et al. Genetically proxied low-density lipoprotein cholesterol lowering via PCSK9-inhibitor drug targets and risk of congenital malformations. *Eur J Prev Cardiol* 2024;**31**:955–965.
8. Lewek J, Bielecka-Dąbrowa A, Toth PP, Banach M. Dyslipidaemia management in pregnant patients: a 2024 update. *Eur Heart J open* 2024;**4**:oeae032.
9. Allevi M, Sarnari S, Giulietti F, Spannella F, Di Pentima C, Sarzani R. Painful and recurring injection site reaction to alirocumab and evolocumab in a young woman with familial hypercholesterolemia and effective therapeutic alternative based on inclisiran: a case report. *Front Cardiovasc Med* 2023;**10**:1181720.
10. Wright RS, Collins MG, Stoekenbroek RM, Robson R, Wijngaard PLJ, Landmesser U, et al. Effects of renal impairment on the pharmacokinetics, efficacy, and safety of inclisiran: an analysis of the ORION-7 and ORION-1 studies. *Mayo Clin Proc England* 2020;**95**:77–89.