



UNIVERSITÀ POLITECNICA DELLE MARCHE
Repository ISTITUZIONALE

Transaxillary approach enhances postoperative recovery after mitral valve surgery

This is the peer reviewed version of the following article:

Original

Transaxillary approach enhances postoperative recovery after mitral valve surgery / Malvindi, Pietro Giorgio; Wilbring, Manuel; De Angelis, Veronica; Bifulco, Olimpia; Berretta, Paolo; Kappert, Utz; Di Eusanio, Marco. - In: EUROPEAN JOURNAL OF CARDIO-THORACIC SURGERY. - ISSN 1010-7940. - 64:1(2023), pp. ezad207.1-ezad207.10. [10.1093/ejcts/ezad207]

Availability:

This version is available at: 11566/319734 since: 2024-12-03T16:13:20Z

Publisher:

Published

DOI:10.1093/ejcts/ezad207

Terms of use:

The terms and conditions for the reuse of this version of the manuscript are specified in the publishing policy. The use of copyrighted works requires the consent of the rights' holder (author or publisher). Works made available under a Creative Commons license or a Publisher's custom-made license can be used according to the terms and conditions contained therein. See editor's website for further information and terms and conditions.

This item was downloaded from IRIS Università Politecnica delle Marche (<https://iris.univpm.it>). When citing, please refer to the published version.

Publisher copyright:

Oxford Academic- Postprint/Author's accepted Manuscript

This is a pre-copyedited, author-produced version of an article accepted for publication in EUROPEAN JOURNAL OF CARDIO-THORACIC SURGERY following peer review. The version of record of the above quoted article is available online at: <https://doi.org/10.1093/ejcts/ezad207>

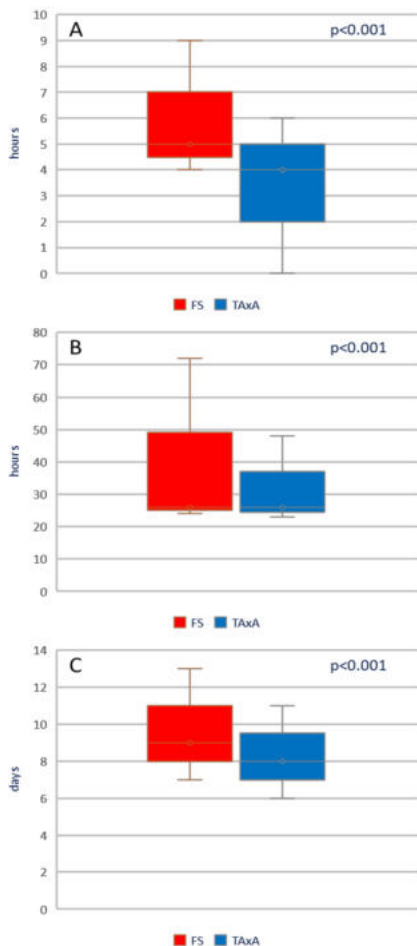
(Article begins on next page)

Early recovery after trans-axillary mitral valve surgery

Summary

Trans-axillary approach provided excellent early clinical results with low in-hospital mortality (0.25%) and postoperative cerebral stroke (0.7%). Compared to classic full sternotomy surgery, minimally invasive mitral valve surgery was associated with shorter mechanical ventilation time, ICU and hospital stay.

Box plot with median and IQR of mechanical ventilation time (A), ICU stay (B) and hospital stay (C) for full sternotomy and trans-axillary matched cohorts.



1 **Title: Trans-axillary approach enhances postoperative recovery after mitral valve surgery**

2 **Running title: Trans-axillary approach for minimally invasive mitral valve surgery**

3 Pietro Giorgio Malvindi^{1*}, Manuel Wilbring^{2*}, Veronica De Angelis², Olimpia Bifulco^{1,3}, Paolo Berretta¹, Utz
4 Kappert², Marco Di Eusanio¹

5 1- Cardiac Surgery Unit, Lancisi Cardiovascular Center, Ospedali Riuniti delle Marche, Polytechnic
6 University of Marche, Ancona, Italy

7 2- Center for Minimally Invasive Cardiac Surgery, University Heart Center Dresden, Dresden, Germany

8 3- Department of Cardiac, Thoracic, Vascular Sciences and Public Health, University of Padua, Padova,
9 Italy

10 * These authors contributed equally

11

12 **Word count:** 4676

13

14

15 Corresponding author:

16 Pietro Giorgio Malvindi

17 Cardiac Surgery Unit, Lancisi Cardiovascular Center, Ospedali Riuniti delle Marche

18 Polytechnic University of Marche

19 Via Conca, 71, 60126 Ancona – Italy

20 p.g.malvindi@univpm.it

21

1 **Visual abstract**

2

3 **Key question:** Does minimally invasive mitral valve surgery offer any clinical advantage over classic full
4 sternotomy approach?

5 **Key findings:** A simplified minimally invasive approach was associated with shorter mechanical ventilation
6 time, ICU and postoperative hospital stay.

7 **Take-home message:** Trans-axillary approach for mitral surgery provided to be safe and supported an early
8 recovery when compared with classic full sternotomy surgery.

9

Abstract

Objectives. Several thoracic incisions have been described and different techniques used for cardiopulmonary bypass, myocardial protection, and valve exposure in minimally invasive mitral valve surgery (MIMVS). Aim of this study is to compare the early outcomes of patients operated using a simplified minimally invasive approach through a right trans-axillary (TxA) access with those achieved with conventional full sternotomy (FS) operations.

Methods. Prospectively collected data of patients who underwent mitral valve surgery between 2017 and 2022 at two academic centres were reviewed. Among them, 454 patients were operated through MIMVS TxA access and 667 patients through FS; associated aortic and CABG procedures, infective endocarditis, redo and urgent operations were excluded. A propensity match analysis was performed using seventeen preoperative variables.

Results. Two well balanced cohorts including a total of 804 patients were analysed. The rate of mitral valve repair was similar in both groups. Operative times were shorter in FS group, nevertheless in patients operated with a minimally invasive approach there was a trend towards decreasing crossclamp time over the study period ($p=0.07$). In TxA group 30-day mortality was 0.25%, postoperative cerebral stroke rate was 0.7%. TxA mitral surgery was associated with shorter intubation time ($p<0.001$) and ICU stay ($p<0.001$). After a median hospital stay of 8 days, 30% of patients who had TxA surgery were discharged home vs. 5% in the FS group ($p<0.001$).

Conclusions. When compared with FS access, TxA approach provides at least similar excellent early outcomes in terms of perioperative morbidity and mortality and allows shorter mechanical ventilation time, ICU and postoperative hospital stay with a higher rate of patients able to be discharged home without any further period of cardiopulmonary rehabilitation.

Abstract word count: 271

Key-words: mitral valve, mitral valve repair, mitral valve replacement, minimally invasive surgery

1 **Introduction**

2 Unarguably, there exists an increasing patients' demand for less trauma, faster recovery, less pain and better
3 cosmesis. This trend has additionally aggravated since percutaneous techniques for aortic or mitral valvular
4 disease had become largely available. Minimally invasive techniques are a promising answer to meet this
5 plausible desire for less trauma. Nonetheless, up to today, still has to proof its advances against the safe and
6 established full sternotomy. Additionally, minimally invasive surgery is no trademark and rather represents
7 a smorgasbord of different techniques and approaches. During the last two decades, several institutional
8 experiences have reported excellent postoperative outcomes showing that mitral surgery through a reduced
9 access is at least as safe and effective as through the classic full sternotomy approach (1)(2). Right mini-
10 thoracotomy has emerged as the favoured thoracic access while several techniques have been proposed and
11 adopted for cardiopulmonary bypass, myocardial protection and surgical exposure. Despite the growing
12 supportive evidence from dedicated high-volume centres, in the real-world practice the adoption of
13 minimally invasive mitral surgery has remained limited (3)(4), probably due to several concerns regarding the
14 potential increase in surgical complexity, the learning curve, the need for further equipment, the associated
15 costs, and the confidence in consolidated outstanding results obtained with classic full sternotomy surgery.

16 The trans-axillary access (TAXA) is a "direct vision-single thoracic incision" simplified surgical technique. It has
17 previously been reported to be safe for aortic, mitral and combined valvular procedures (5-8). Hereby, the
18 trans-axillary access is characterised by a simplified surgical setup without the need for expensive video
19 equipment or additional transthoracic instruments. Nonetheless, the available clinical data on this simplified,
20 but innovative access route is limited. For those purposes, the present study evaluates the results of a large
21 trans-axillary cohort of patients undergoing isolated mitral surgery, compared with those achieved in a
22 contemporary cohort of patients operated through a full sternotomy (FS) access.

23

24

1 **Materials and methods**

2 *Ethical statement, study design, data collection and outcomes*

3 This study is a multicentre retrospective outcome evaluation from institutional records with prospective data
4 entry. Patients' data were retrieved from the internal database of Cardiac Surgery Unit at Lancisi
5 Cardiovascular Centre in Ancona (Italy) (approval CERM 2019 361) and the Center for Minimally Invasive
6 Cardiac Surgery at the University Heart Center Dresden in Dresden (Germany) (approval EK 298092012).
7 Several preoperative, intraoperative and postoperative data were collected as reported in Tables 1-3.

8

9 *Population*

10 The population of this study includes consecutive 1121 patients who underwent first-time isolated mitral
11 valve surgery at two academic centres during the period January 2017 – June 2022. Concomitant aortic and
12 CABG procedures, infective endocarditis and urgent operations were excluded. Among these 454 patients
13 underwent minimally invasive surgery using a trans-axillary approach. A total of 667 patients who underwent
14 mitral surgery through a classic full sternotomy access. The final study group consisted of 804 patients and
15 was generated by 1:1 propensity score matching out of the entire cohort, accordingly with 402 patients in
16 each group.

17

18 *Definitions*

19 The definition of preoperative characteristics aligns with the notes about EuroSCORE (9). Early mortality and
20 complications refer to events that occurred in the first 30 days since the operation. Postoperative outcomes
21 were recorded according to the VARC-2 criteria (10).

22

23

1 *Echocardiography*

2 Before the operation all the patients underwent echocardiographic examination (trans-thoracic, TTE, and
3 trans-oesophageal, TOE) by the core echocardiography laboratory at each institutional site. A pre-discharge
4 TTE control was performed usually on day 4 to day 6 after the operation. The assessment of heart valve
5 pathologies and their grading were in accordance with the current recommendations and guidelines.

6

7 *Surgical techniques*

8 All patients received general anaesthesia and TOE was performed before and during the operation for
9 monitoring and evaluation of the surgical result. Trans-axillary approach was developed by the two centres
10 as a shared and progressive refinement starting from the initial experience with minimally invasive mitral
11 surgery through an antero-lateral mini-thoracotomy access.

12

13 *1. Trans-axillary access*

14 The trans-axillary access was performed as described previously (5-8). In shorty, with the patient on supine
15 position, a 4 to 6 cm skin incision was made in the right anterior axillary line at the level of the 4th intercostal
16 space. Cardiopulmonary bypass was established through femoral vessels cannulation using Seldinger
17 technique and TOE guidance after surgical cut-down. Occasionally a venous cannula for CPB return was
18 placed in the right jugular vein before surgical draping. Once extracorporeal circulation was established,
19 pericardium was opened and stay sutures were placed. The aorta was occluded using a flexible clamp
20 introduced through the mini-thoracotomy access and crystalloid cardioplegia was then delivered through a
21 needle in the ascending aorta. The left atrium was opened using a left atrial atriotomy in the inter-atrial
22 groove. The mitral valve apparatus was exposed on direct vision with the aid of an atrial retractor, no video
23 assistance tool was used. Video supports are available at <https://www.minicardiacsurgery-univpm->

1 [research.com/video-gallery/](https://www.research.com/video-gallery/) - <https://www.youtube.com/watch?v=GmT0iq34Qx0> and in previous
2 publication (7).

3

4 *2. Full Sternotomy access*

5 Full sternotomy access included a complete median sternotomy, opening of the pericardium and placement
6 of usual stay sutures. Cardiopulmonary bypass was generally instituted after distal ascending aorta and
7 bicaval cannulation. A left ventricular vent line was placed through the right upper pulmonary vein. After
8 aortic cross-clamping, antegrade histidine-tryptophan-ketoglutarate (Custodiol®) or del Nido cardioplegia
9 was delivered in the ascending aorta. The mitral valve was exposed after a direct left atriotomy through the
10 interatrial groove or using a trans-septal access depending on the surgeon's preference.

11

12 *3. Techniques of mitral valve surgery*

13 All conventionally applicable surgical techniques were used for minimally invasive and full sternotomy mitral
14 valve surgery. Several mitral repair techniques, such as leaflet resection, implantation of artificial chords and
15 annuloplasty rings were used. For mitral valve replacement common stented biologic or mechanical
16 substitutes were implanted using interrupted sutures with pledgets.

17

18 *Statistical analysis*

19 Patients were divided into two groups according to trans-axillary (TAXA) and full sternotomy (FS) access.
20 To minimize the effects of selection bias and to generate two ideally matched cohorts of patients, a
21 propensity matching analysis was performed using the following preoperative variables:

22 *age (years), gender, BMI, hypertension, dyslipidaemia, diabetes mellitus, smoking history, history of*
23 *cerebrovascular accident, history of coronary artery disease, chronic kidney disease (eGFR<50*

1 mL/min/1.73m²), NYHA class≥III, history of atrial fibrillation, mitral valve regurgitation, left ventricular
2 ejection fraction, pulmonary hypertension (pulmonary artery pressure≥30 mmHg), tricuspid regurgitation
3 more than moderate, EuroSCORE II.

4 The nearest matching algorithm was applied with a caliper width for the logit of the propensity score less
5 than 0.2. The adequacy of propensity score matching was evaluated on standardised mean difference values
6 for each variable and was considered acceptable when the absolute value was less than 0.1 (11). Continuous
7 variables were expressed as mean ± SD or median with interquartile range (IQR). Categorical variables were
8 expressed as frequencies and percentages. Comparisons of preoperative, intraoperative and postoperative
9 variables were performed between the two groups of patients using the appropriate test (Student's t-test or
10 Mann-Whitney U test, χ^2 or Fisher's exact test).

11 Linear regression was performed to study the relationship between Log₁₀ operative times and the temporal
12 progression of minimally invasive mitral valve surgery cases. Kolmogorov-Smirnov test was used to test the
13 normality of residuals.

14 The analysis was generated using Statistical Analysis Software (SAS), Version 3.8, SAS University Edition (SAS
15 Institute Inc., Cary, NC).

16

1 **Results**

2 *Baseline characteristics*

3 The preoperative characteristics of the unmatched overall population, trans-axillary and full sternotomy
4 groups are summarised in Table 1. Before matching, patients who underwent mitral surgery through a FS
5 access were older with higher rates of comorbidities and risk factors. Propensity match analysis provided two
6 well balanced groups of 402 patients each with non-significantly differing preoperative characteristics (Figure
7 1, Table 1).

8 9 *Intraoperative data*

10 The rate of mitral repair was similar in both groups, as were the sites of repair according to mitral leaflets
11 involvement. Resection was more commonly performed in patients who had FS access (33% vs 15%, $p < 0.001$)
12 while implantation of artificial chords was mostly used in TAxA approach (61% vs 23%, $p < 0.001$). Operative
13 times were shorter in the FS group with a mean CPB time 78 ± 29 minutes vs. 99 ± 31 minutes in TAxA ($p < 0.001$)
14 and crossclamp time 60 ± 22 minutes in FS vs 65 ± 22 minutes in TAxA-group ($p = 0.002$), respectively. **In the**
15 **minimally invasive group, the length of crossclamp time showed a progressive reduction throughout the**
16 **experience: Log_{10} crossclamp time parameter estimate was -0.00022675 , 95% CI -0.00047471 , 0.00002121 ;**
17 **($p = 0.07$; normality test $p = 0.1$). A similar trend was not found for cardiopulmonary bypass time: Log_{10}**
18 **cardiopulmonary bypass time parameter estimate was -0.00000575 , 95%CI -0.00024182 , 0.00023031 ;**
19 **($p = 0.96$; normality test $p = 0.06$). Table 2 provides details about operative data.**

20

21 *Postoperative outcomes*

22 The overall 30-day mortality rate was 0.7% ($n = 6/804$). In the FS-group 30-days mortality was 1.2% ($n = 5/402$),
23 and 0.3% ($n = 1/402$) in TAxA-group, which gained no statistical significance ($p = 0.21$). No significant
24 differences were observed between the two groups of patients – FS vs. TAxA - concerning cerebral stroke

1 with 2.2% (n=9/402) vs 0.7% (n=3/402; p=0.14), re-exploration for bleeding with 3.9% (n=16/402) vs 4.2%
2 (n=17/402; n=0.86), respiratory failure with 2.2% (n=9/402) vs 1.9% (n=8/402; p=0.80) and occurrence of
3 postoperative atrial fibrillation 31.9% (n=86/270) vs 28.2% (n=78/277; p=0.34), respectively. TAxA-patients
4 had a shorter postoperative mechanical ventilation time with a median of 4 hours [0-6] vs. 5 hours [4-9] in
5 the full sternotomy group (p<0.001). After TAxA mitral surgery, 26.4% (n=106/402) of the patients were
6 extubated on table soon after the completion of the procedure, which was significantly more compared to
7 3.9% (n=16/402) after full sternotomy surgery (p<0.001). TAxA approach was associated with significant
8 lower rates of red blood cells transfusions and postoperative kidney dysfunction requiring renal replacement
9 therapy (Table 3). Patients operated on with full sternotomy experienced a longer ICU and postoperative
10 hospital stay with only a minority of patients – 5.4% (n=22/402) vs 28.6% (n=115/402) in trans-axillary group
11 – able to be discharged home without the need of any further cardiopulmonary rehabilitation or
12 physiotherapist support. Table 3 details about postoperative outcomes. See Figure 2 and Figure 3.

13

14 **Comment**

15 Minimally invasive mitral valve surgery through TAxA access was associated with excellent early results. The
16 analysis of the common hard endpoints after cardiac surgery showed that early outcomes were outstanding
17 for both FS and TAxA approaches with minimally invasive surgery characterised by a lower 30-day mortality
18 (0.25%) and postoperative cerebral stroke (0.7%). Patients who underwent TAxA surgery experienced a
19 shorter mechanical ventilation time with more than one fourth of the patients extubated on table soon after
20 the completion of the surgical procedure. The postoperative mechanical ventilation time and ICU stay were
21 shorter in TAxA group as it was the overall postoperative hospital stay with a higher number of patients able
22 to be discharged home without any further period of rehabilitation. A TAxA access was furthermore
23 associated with a reduced occurrence of severe postoperative kidney dysfunction requiring renal
24 replacement therapy, a lower number of patients receiving blood transfusion(s), a lower rate of deep wound
25 complications, thus confirming previous findings from institutional reports and meta-analyses highlighting

1 that surgical mini mitral operations are safe (1)(12) and bring lower postoperative morbidity (2)(13)(14)
2 without any extra cost (12)(15) when compared with classic full sternotomy surgery.

3 The trans-axillary approach, while guaranteeing a reduced chest wall trauma with a 4-6 cm incision that,
4 hidden in the axilla, remains invisible (Figures 4 and 5), provides a favourable surgical setting to the operating
5 surgeons by allowing - through direct vision - an optimal exposure of the aortic/mitral/tricuspid valves, the
6 ascending aorta, the interatrial groove and the venae cavae. This more posteriorly and cranially located
7 access enhances direct view minimally invasive surgery with 1) a perpendicularly trajectory to the valves, 2)
8 reduce surgeon-to-valve distance, 3) perfect eye-hand alignment and ergonomics (Video 1 e 2).

9 Of note, our data showed that TAXA surgery did not impact the type and the conduct of mitral valve
10 procedures and was characterised by a low rate of repeated crossclamp, occurrence of intraoperative systolic
11 anterior motion and left circumflex occlusion, which were moreover similar to FS approach. Tricuspid repair
12 was performed with the same direct vision exposure, and we registered no difference between full
13 sternotomy and trans-axillary group with a rate of associated tricuspid procedures which averages the
14 common range reported in literature (3,16-18).

15 Minimally invasive mitral valve surgery has been ubiquitously associated with longer CPB and crossclamp
16 times with cardiac ischaemic time exceeding 90-110 minutes and extracorporeal circulation time well over 2
17 hours (1)(12)(15)(19,20). In our experience, trans-axillary access was associated with shorter operative times
18 – 65 minutes mean crossclamp time and 99 minutes mean extracorporeal circulation time - which still appear
19 favourable when compared with FS surgery (60 minutes mean crossclamp time, 78 minutes mean CPB time),
20 especially when considering that the progression of the experience in TAXA approach was associated with a
21 reduction in cardiac ischaemic time.

22 Despite the outstanding results from dedicated Institutions and practices, the penetration of minimally
23 invasive surgery is still limited as national and multi-institutional databases showed that mini-thoracotomy
24 mitral surgery has been performed in recent years in 23% to 54% of patients undergoing mitral procedures
25 (3)(4)(21)(22). A reduced surgical access and a smaller surgical field can be viewed as feared pitfalls for

1 adequate exposure, myocardial protection and deairing, translating into longer operative times and
2 potentially preventing a prompt and optimal management of intraoperative complications. Trans-axillary
3 approach has the potential to spread the adoption of MIMVS since it has shown to be attractive beyond a
4 mere cosmetic purpose, by enhancing mitral exposure without increasing the surgical complexity, producing
5 similar outstanding early results that many surgeons and patients have been used for decades with classic
6 full sternotomy surgery, and most importantly by supporting an early recovery and discharge.

7 Regarding the generalization of these results, our study presents some limitations. The several differences
8 between the unmatched populations suggests that the choice of the surgical access was influenced by
9 preoperative patients' clinical profile with patients undergoing FS procedure being at higher risk. However,
10 propensity match analysis returned two well balanced cohorts of patients with mean age of 65 years,
11 advanced symptoms in more than 40% of the cases, history of CKD and CAD in about 15% of the cases and
12 high prevalence of preoperative atrial fibrillation. Since the postoperative imaging data are limited to pre-
13 discharge evaluation, no assumptions can be made regarding mid/long-term durability of mitral valve
14 procedure.

15 Within these limitations, we found that a simplified minimally invasive approach through a TaxA access and
16 direct vision, was associated with a high rate of mitral valve repair, outstanding early outcomes and enhanced
17 patients' recovery characterised by shorter ventilation time, ICU and hospital stay when compared with a
18 matched group of patients undergoing full sternotomy surgery. Having achieved a shared and reproducible
19 high safety profile in mitral surgery with a risk of postoperative mortality and major morbidity <1%, these
20 former "secondary" outcomes should be regarded as the new therapeutic targets aiming to a faster
21 postoperative recovery and a quicker improvement of the quality of life. Further data are needed to evaluate
22 the impact of TaxA approach on social and occupational reintegration and to confirm the durability of mitral
23 procedures.

1 **Conflict of interest:** none declared

2 **Funding statement:** no fund

3 **Data availability statement:** The data underlying this article will be shared on reasonable request to the
4 corresponding author

5

1 **References**

- 2 1. Sá MPBO, Van den Eynde J, Cavalcanti LRP, Kadyraliev B, Enginoev S, Zhigalov K, et al. Mitral valve repair
3 with minimally invasive approaches vs sternotomy: A meta-analysis of early and late results in
4 randomized and matched observational studies. *J Card Surg.* 2020;35:2307-2323
- 5 2. Eqbal AJ, Gupta S, Basha A, Qiu Y, Wu N, Rega F, et al. Minimally invasive mitral valve surgery versus
6 conventional sternotomy mitral valve surgery: A systematic review and meta-analysis of 119 studies. *J*
7 *Card Surg.* 2022;37:1319-1327
- 8 3. Olsthoorn JR, Heuts S, Houterman S, Maessen JG, Sardari Nia P; Cardiothoracic Surgery Registration
9 Committee of the Netherlands Heart Registration. Effect of minimally invasive mitral valve surgery
10 compared to sternotomy on short- and long-term outcomes: a retrospective multicentre interventional
11 cohort study based on Netherlands Heart Registration. *Eur J Cardiothorac Surg.* 2022;61:1099-1106
- 12 4. Badhwar V, Vemulapalli S, Mack MA, Gillinov AM, Chikwe J, Dearani JA, et al. Volume-Outcome
13 Association of Mitral Valve Surgery in the United States. *JAMA Cardiol.* 2020;5:1092-1101
- 14 5. Wilbring M, Alexiou K, Schmidt T, Petrov A, Taghizadeh-Waghefi A, et al. Safety and Efficacy of the
15 Transaxillary Access for Minimally Invasive Aortic Valve Surgery. *Medicina (Kaunas).* 2023;59:160
- 16 6. Taghizadeh-Waghefi A, Arzt S, De Angelis V, Schiffarth J, Petrov A, Tomko M, et al. Safety and Efficacy of
17 the Transaxillary Access for Minimally Invasive Mitral Valve Surgery-A Propensity Matched Competitive
18 Analysis. *Medicina (Kaunas).* 2022;58:1850
- 19 7. Wilbring M, Arzt S, Alexiou K, Matschke K, Kappert U. Surgery without visible scars-double valve surgery
20 using the right lateral access. *Ann Cardiothorac Surg.* 2020;9:424-426. doi: 10.21037/acs.2020.03.16
- 21 8. Wilbring M, Matschke KE, Alexiou K, Di Eusanio M, Kappert U. Surgery without Scars: Right Lateral Access
22 for Minimally Invasive Aortic Valve Replacement. *Thorac Cardiovasc Surg.* 2021;69:461-465
- 23 9. Nashef SA, Roques F, Sharples LD, Nilsson J, Smith C, Goldstone AR, et al. EuroSCORE II. *Eur J Cardiothorac*
24 *Surg* 2012;41:734-44

- 1 10. Kappetein AP, Head SJ, Génèreux P, Piazza N, van Mieghem NM, Blackstone EH, et al. Updated
2 standardized endpoint definitions for transcatheter aortic valve implantation: the Valve Academic
3 Research Consortium-2 consensus document. *J Am Coll Cardiol* 2012;60:1438-54
- 4 11. Benedetto U, Head SJ, Angelini GD, Blackstone EH. Statistical primer: propensity score matching and its
5 alternatives. *Eur J Cardiothorac Surg.* 2018;53:1112-1117
- 6 12. Downs EA, Johnston LE, LaPar DJ, Ghanta RK, Kron IL, Speir AM, et al. Minimally Invasive Mitral Valve
7 Surgery Provides Excellent Outcomes Without Increased Cost: A Multi-Institutional Analysis. *Ann Thorac*
8 *Surg.* 2016;102:14-21
- 9 13. Berretta P, De Angelis V, Alfonsi J, Pierri MD, Malvindi PG, Zahedi HM, et al. Enhanced recovery after
10 minimally invasive heart valve surgery: Early and midterm outcomes. *Int J Cardiol.* 2023 Jan 1;370:98-104
- 11 14. Sabatino ME, Okoh AK, Chao JC, Soto C, Baxi J, Salgueiro LA, et al. Early Discharge After Minimally Invasive
12 Aortic and Mitral Valve Surgery. *Ann Thorac Surg.* 2022;114:91-97
- 13 15. Perin G, Shaw M, Toolan C, Palmer K, Al-Rawi O, Modi P. Cost Analysis of Minimally Invasive Mitral Valve
14 Surgery in the UK National Health Service. *Ann Thorac Surg.* 2021;112:124-131
- 15 16. Kastengren M, Svenarud P, Källner G, Franco-Cereceda A, Liska J, Gran I, et al. Minimally invasive versus
16 sternotomy mitral valve surgery when initiating a minimally invasive programme. *Eur J Cardiothorac Surg.*
17 2020 Dec 1;58(6):1168-1174)
- 18 17. Van Praet KM, Kofler M, Hirsch S, Akansel S, Hommel M, Sündermann SH, et al. Factors associated with
19 an unsuccessful fast-track course following minimally invasive surgical mitral valve repair. *Eur J*
20 *Cardiothorac Surg.* 2022;62:ezac451
- 21 18. Bonaros N, Hoefler D, Oezpeker C, Gollmann-Tepeköylü C, Holfeld J, Dumfarth J, et al. Predictors of safety
22 and success in minimally invasive surgery for degenerative mitral disease. *Eur J Cardiothorac Surg.*
23 2022;61:637-644
- 24 19. Grossi EA, Goldman S, Wolfe JA, Mehall J, Smith JM, Ailawadi G, et al; Economic Workgroup on Valvular
25 Surgery. Minithoracotomy for mitral valve repair improves inpatient and postdischarge economic
26 savings. *J Thorac Cardiovasc Surg.* 2014;148:2818-22

- 1 20. Goldstone AB, Atluri P, Szeto WY, Trubelja A, Howard JL, MacArthur JW Jr, et al. Minimally invasive
2 approach provides at least equivalent results for surgical correction of mitral regurgitation: a propensity-
3 matched comparison. *J Thorac Cardiovasc Surg.* 2013;145:748-56
- 4 21. Beckmann A, Meyer R, Lewandowski J, Markewitz A, Blaßfeld D, Böning A. German Heart Surgery Report
5 2021: The Annual Updated Registry of the German Society for Thoracic and Cardiovascular Surgery.
6 *Thorac Cardiovasc Surg.* 2022;70:362–376
- 7 22. Gammie JS, Chikwe J, Badhwar V, Thibault DP, Vemulapalli S, Thourani VH, et al. Isolated Mitral Valve
8 Surgery: The Society of Thoracic Surgeons Adult Cardiac Surgery Database Analysis. *Ann Thorac Surg.*
9 2018;106:716-727

Tables

Table 1. Preoperative patients' characteristics in unmatched and matched populations

| Variables | Overall N=1121 | Unmatched | | | Matched | | |
|--|-------------------|------------------|------------------|-----------------|------------------|------------------|-----------------|
| | | FS N=667 | TxA N=454 | Absolute SMD | FS N=402 | TxA N=402 | Absolute SMD |
| | mean±SD n (%) | mean±SD n (%) | mean±SD n (%) | | mean±SD n (%) | mean±SD n (%) | |
| Age (years) | 66±11 | 67±10 | 64±12 | 0.291 | 65±11 | 65±11 | 0.021 |
| Gender (M/F) | 593/528 | 325/342 | 268/186 | 0.212 | 228/174 | 233/169 | 0.025 |
| BMI (kg/m ²) | 26.1±4.5 | 26.5±4.5 | 25.5±4.3 | 0.257 | 25.7±3.8 | 25.6±4.3 | 0.029 |
| BSA (m ²) | 1.87±0.22 | 1.86±0.21 | 1.87±0.22 | 0.047 | 1.86±0.21 | 1.87±0.23 | 0.045 |
| Hypertension | 799 (72) | 509 (77) | 290 (64) | 0.270 | 276 (69) | 270 (67) | 0.033 |
| Diabetes Mellitus | 154 (14) | 110 (16) | 44 (10) | 0.202 | 48 (12) | 42 (11) | 0.044 |
| Dyslipidaemia | 450 (40) | 305 (46) | 145 (32) | 0.285 | 153 (38) | 144 (36) | 0.046 |
| Smoking history | 176 (16) | 99 (15) | 77 (17) | 0.060 | 68 (17) | 67 (17) | 0.007 |
| CKD (eGFR<50 mL/min/1.73m ²) | 216 (19) | 159 (24) | 57 (13) | 0.289 | 61 (15) | 56 (14) | 0.033 |

| | | | | | | | |
|-------------------------------------|-----------|-----------|-----------|-------|-----------|-----------|-------|
| Peripheral Arteriopathy | 22 (2) | 14 (2) | 8 (2) | 0 | 7 (2) | 7 (2) | 0 |
| Previous cerebral stroke | 70 (6) | 43 (6) | 27 (6) | 0.014 | 28 (7) | 25 (6) | 0.031 |
| Previous CAD | 170 (15) | 116 (17) | 54 (12) | 0.147 | 60 (15) | 53 (13) | 0.049 |
| Previous PCI | 82 (7) | 55 (8) | 27 (6) | 0.078 | 33 (8) | 27 (7) | 0.038 |
| NYHA class≥III | 557 (50) | 362 (54) | 195 (43) | 0.231 | 186 (46) | 182 (45) | 0.020 |
| Permanent pacemaker | 62 (6) | 46 (7) | 16 (4) | 0.132 | 22 (5) | 14 (3) | 0.102 |
| History of AF | 407 (36) | 277 (42) | 130 (29) | 0.276 | 132 (33) | 125 (31) | 0.037 |
| Preoperative AF | 377 (34) | 259 (39) | 118 (26) | 0.280 | 122 (30) | 114 (28) | 0.044 |
| Haemoglobin (g/dl) | 13.4±1.6 | 13.4±1.6 | 13.5±1.5 | 0.064 | 13.5±1.6 | 13.5±1.6 | 0 |
| Haematocrit (%) | 40.3±4.4 | 40.0±4.5 | 40.7±4.3 | 0.158 | 40.5±4.4 | 40.6±4.2 | 0.023 |
| Preoperative ventricular arrhythmia | 14 (1) | 5 (1) | 9 (2) | 0.373 | 3 (1) | 7 (2) | 0.310 |
| LVEF (%) | 58±11 | 57±12 | 60±10 | 0.186 | 58±12 | 59±11 | 0.025 |
| Pure mitral regurgitation | 1025 (91) | 592 (89) | 433 (95) | 0.257 | 383 (95) | 383 (95) | 0 |
| PAPs≥30 mmHg | 622 (55) | 408 (61) | 214 (47) | 0.291 | 207 (51) | 203 (51) | 0.020 |
| Tricuspid regurgitation ≥ moderate | 374 (34) | 240 (36) | 134 (30) | 0.146 | 125 (31) | 116 (29) | 0.049 |
| EuroSCORE II (%) | 1.56±1.42 | 1.74±1.61 | 1.30±1.03 | 0.317 | 1.42±1.52 | 1.36±1.07 | 0.054 |

AF, atrial fibrillation; BMI, body mass index; BSA, body surface area; CAD, coronary artery disease; CKD, chronic kidney disease; eGFR, glomerular filtration rate; LVEF, left ventricular ejection fraction; NYHA, New York Heart Association; PAPs, systolic pulmonary artery pressure; PCI, percutaneous coronary intervention; SMD, standardised mean difference.

Table 2. Operative data

| Variables | Matched | | |
|--|--|--|--------|
| | FS N=402 | TxA N=402 | p |
| | mean±SD or median [IQR] n (%) | mean±SD or median [IQR] n (%) | |
| Mitral repair for MR | 318/383 (83) | 310/383 (81) | 0.45 |
| Mitral repair for PMVL prolapse | 162/186 (87) | 196/229 (86) | 0.66 |
| Mitral repair for AMVL prolapse | 31/45 (69) | 15/21 (71) | 0.83 |
| Mitral repair for bileaflets disease | 43/53 (81) | 60/67 (90) | 0.19 |
| Neochordae | 74/318 (23) | 190/310 (61) | <0.001 |
| Leaflet(s) resection | 106/318 (33) | 48/310 (15) | <0.001 |
| Edge-to-edge | 45/318 (15) | 31/310 (10) | 0.10 |
| Concomitant TV repair | 40 (10) | 33 (8) | 0.39 |
| Concomitant AF surgery | 74 (18) | 24 (6) | <0.001 |
| Cardiopulmonary bypass time (minutes) | 78±29 | 99±31 | <0.001 |
| Cross-clamp time (minutes) | 60±22 | 65±22 | 0.002 |
| Repeated Cross-clamp | 17 (4) | 10 (2) | 0.17 |
| Intraoperative SAM | 3 (1) | 8 (2) | 0.22 |
| Intraoperative LCx occlusion | 0 | 1 (0.25) | 1.0 |
| Intraoperative aortic dissection | 0 | 1 (0.25) | 1.0 |

AF, atrial fibrillation; AMVL, anterior mitral valve leaflet; LCx, left circumflex artery; MR, mitral regurgitation; PMVL, posterior mitral valve leaflet; SAM, systolic anterior motion; TV, tricuspid valve

Table 3. Postoperative data

| Variables | Matched | | |
|---|--|--|--------|
| | FS N=402 | TxA N=402 | p |
| | mean±SD or median [IQR] n (%) | mean±SD or median [IQR] n (%) | |
| 30-day mortality | 5 (1) | 1 (0.25) | 0.21 |
| Cerebral stroke | 9 (2) | 3 (0.7) | 0.14 |
| Postoperative myocardial infarction | 9 (2) | 6 (1) | 0.43 |
| CVVHD | 20 (5) | 3 (0.7) | <0.001 |
| Bleeding re-thoracotomy | 16 (4) | 17 (4) | 0.86 |
| | | | |
| On table extubation | 16 (4) | 106 (26) | <0.001 |
| Mechanical ventilation time (hours) | 5 [4-9] | 4 [0-6] | <0.001 |
| Respiratory failure | 9 (2) | 8 (2) | 0.80 |
| ICU stay (hours) | 26 [24-72] | 26 [23-48] | <0.001 |
| | | | |
| New onset AF (preoperative SR) | 86/270 (32) | 78/277 (28) | 0.34 |
| Permanent pacemaker | 18 (4) | 16 (4) | 0.73 |
| Deep wound complication | 17 (4) | 7 (2) | 0.04 |
| Pre-discharge red blood cells transfusion (number of patients) | 100 (25) | 72 (18) | 0.02 |
| | | | |

| | | | |
|------------------------|----------|----------|--------|
| Hospital stay (days) | 9 [7-13] | 8 [6-11] | <0.001 |
| Discharge Home | 20 (5) | 115 (29) | <0.001 |
| LVEF (%) | 52±11 | 52±9 | 0.97 |
| Residual moderate MR | 22 (5) | 17 (4) | 0.41 |
| Redo for early failure | 10 (2) | 3 (1) | 0.05 |

AF, atrial fibrillation; CVVHD, continuous veno-venous haemodialysis; ICU, Intensive Care Unit; LVEF, left

ventricular ejection fraction; MR, mitral regurgitation; SR, sinus rhythm

Figures

Central image. Early outcomes of minimally invasive trans-axillary approach and full sternotomy mitral valve surgery.

Figure 1. Standardised mean differences of preoperative characteristics included in the propensity match analysis before (blue) and after matching (red).

Figure 2. Box plot with median and IQR of mechanical ventilation time (A), ICU stay (B) and hospital stay (C) for full sternotomy and trans-axillary matched cohorts.

Figure 3. Postoperative outcomes in full sternotomy and trans-axillary matched cohorts. CVVHD: continuous veno-venous haemodialysis; PPM; permanent pacemaker. * $p < 0.05$.

Figure 4. Trans-axillary incision, view from lateral and frontal side (with the consent of the patient).

Figure 5. Panels A and B: Intraoperative setup with positioning of the patient in supine position slightly rotated to the left. The arm is placed in a “Javelin-thrower”-position. A 5 cm skin incision in the right anterior axillary line (white arrows) allows access to the 4th intercostal space. Panel C: Inspection of the mitral valve with the. The valve can be reached with a standard forceps (*). Panel D: Intraoperative view after annuloplasty. Panel E: Postoperative cosmetic result (circle).

Videos

Video 1. Head camera view mimicking 90° trajectory direct vision of mitral valve through trans-axillary access.

Video 2. Head camera view mimicking 90° trajectory direct vision of subvalvular apparatus through trans-axillary access.

Figure 1

[Click here to access/download;Figure;Figure 1 revised.pdf](#)

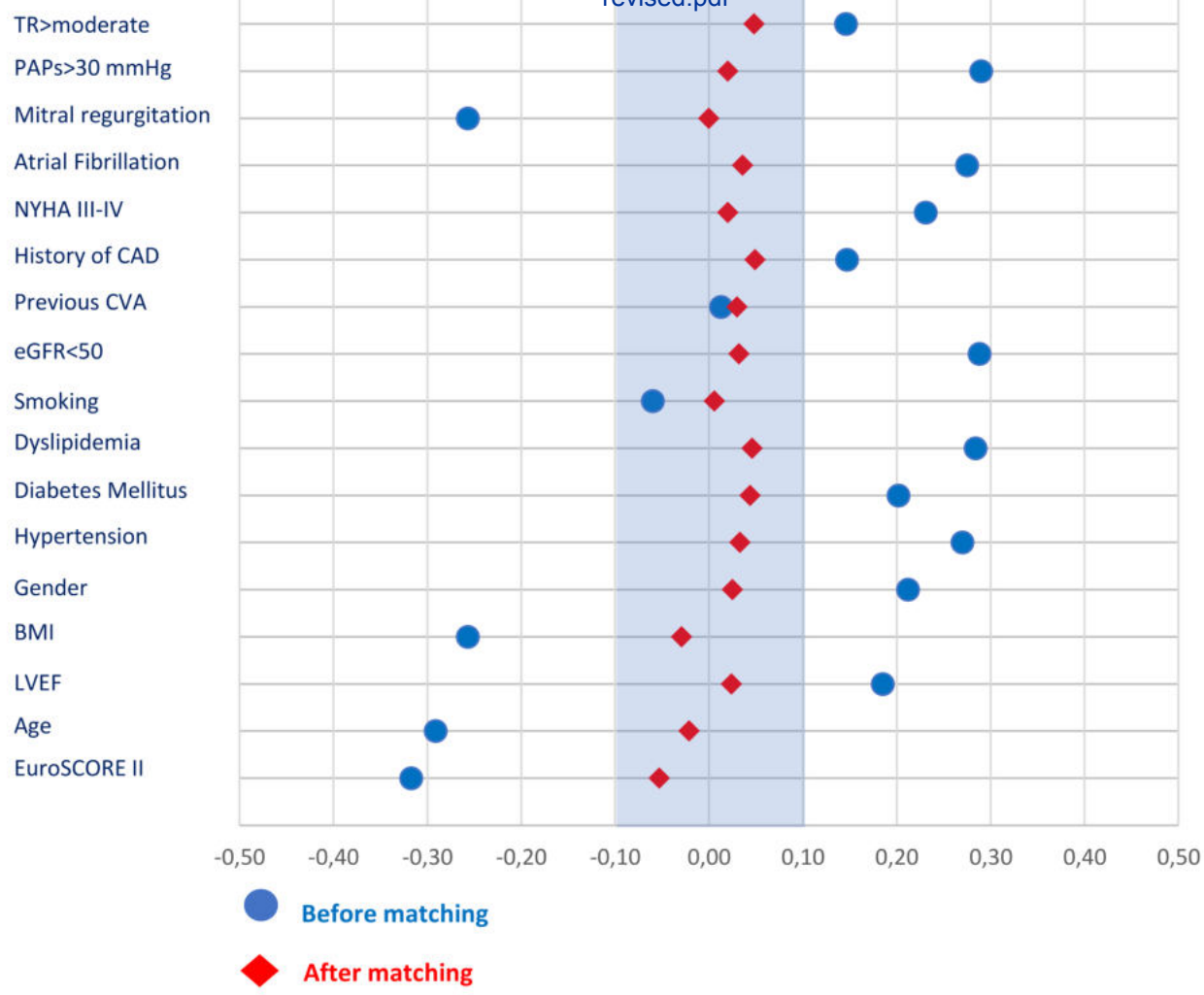


Figure 2

[Click here to access/download;Fi](#)

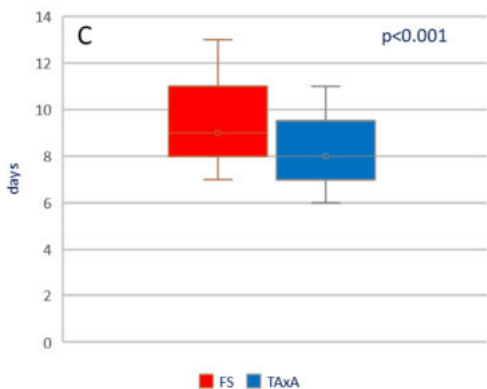
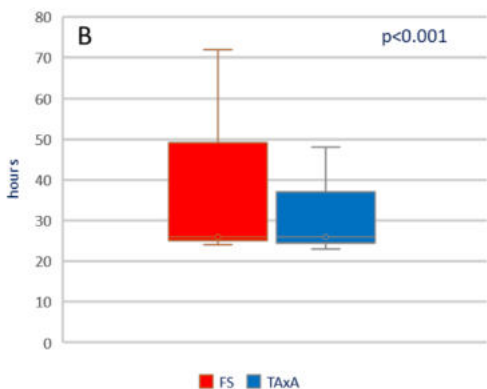
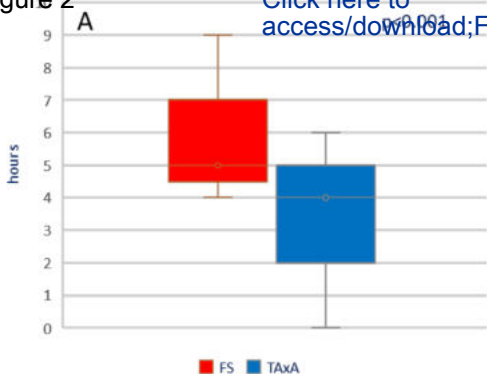


Figure 3

[Click here to access/download;Figure;Figure 3 revised.pdf](#)

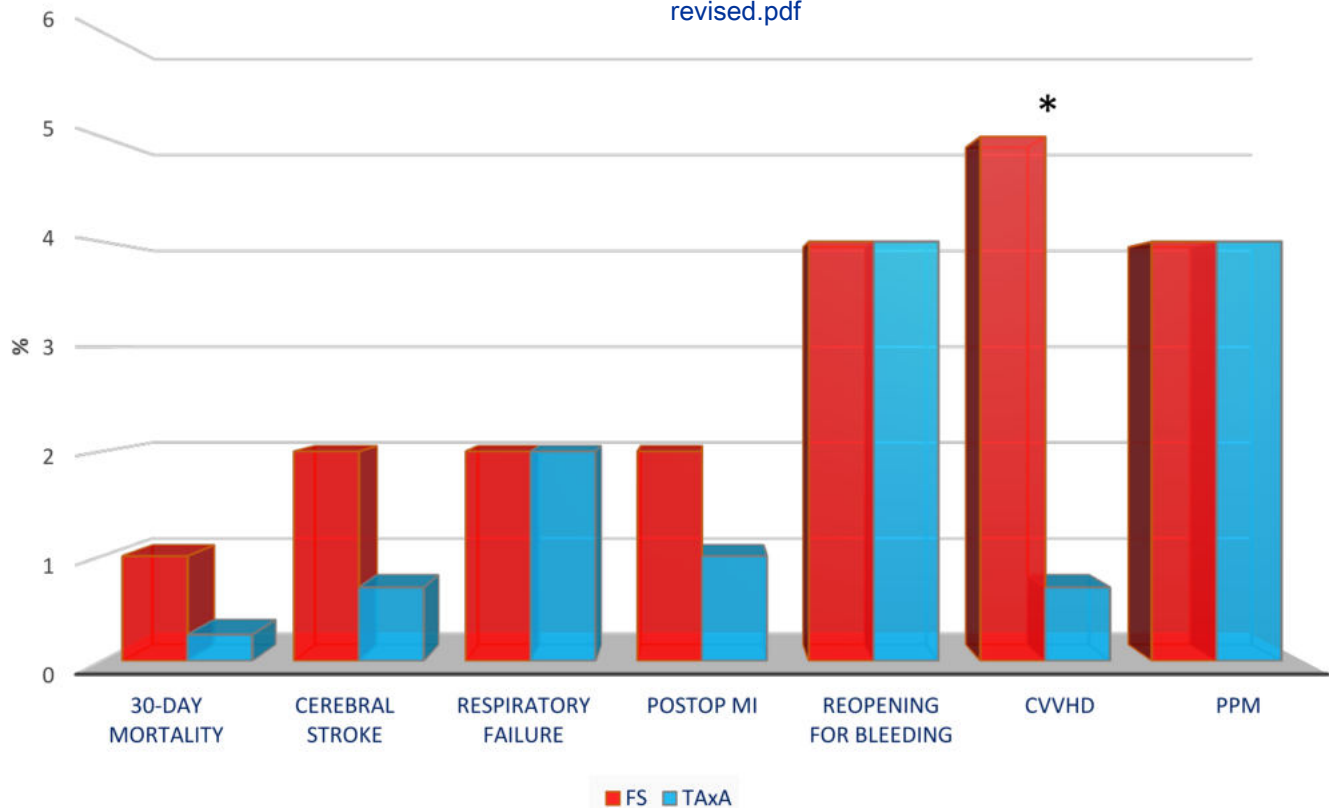
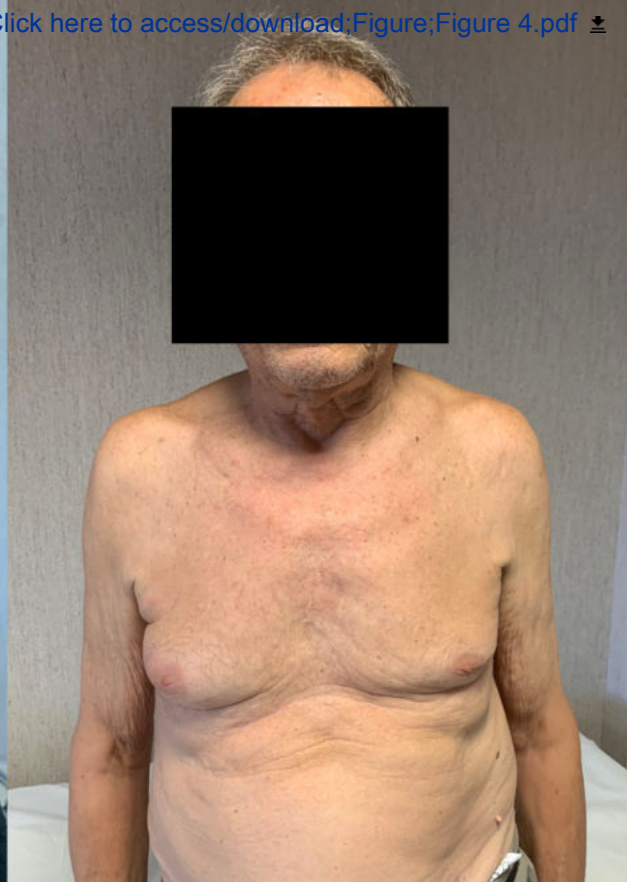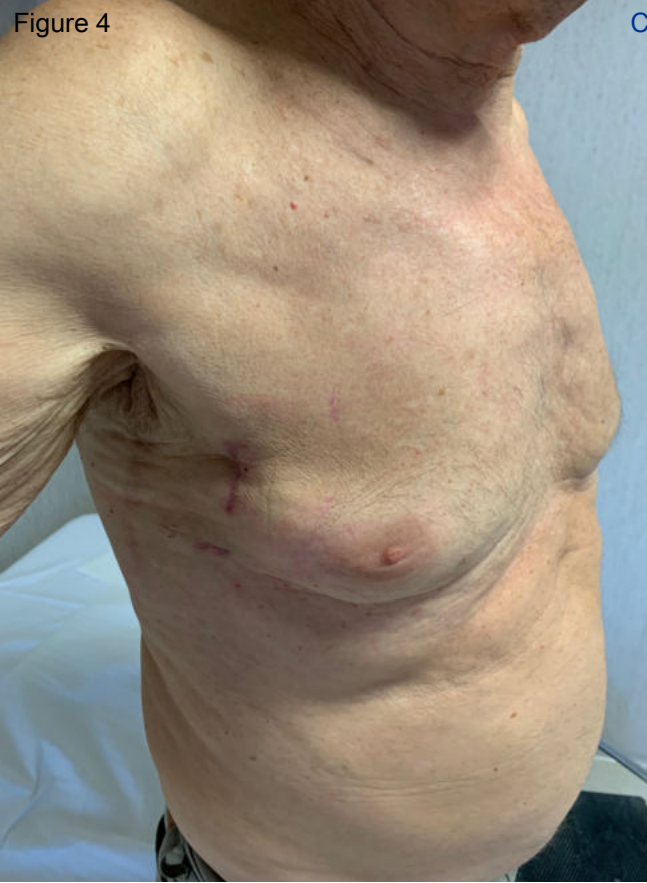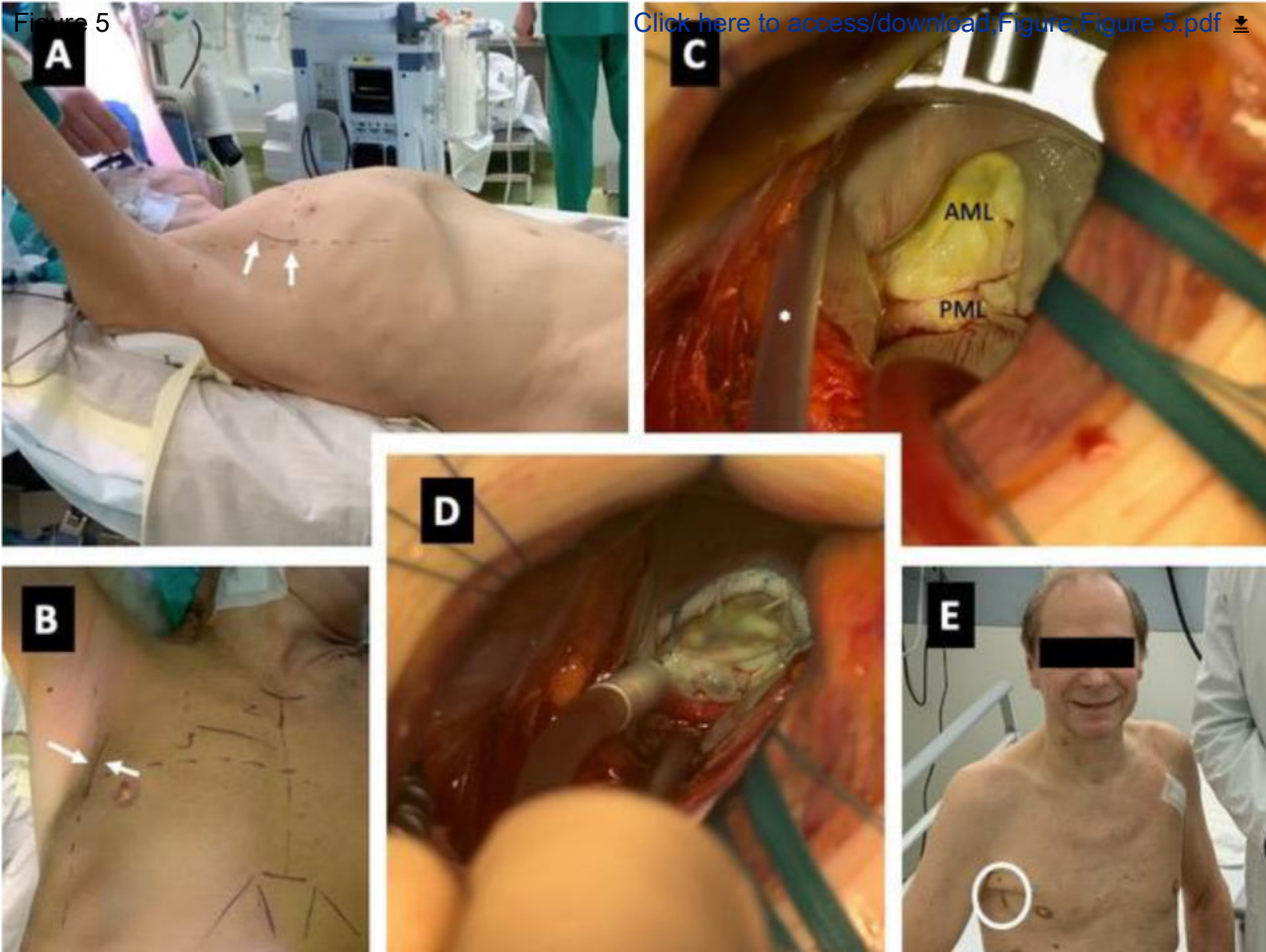


Figure 4

[Click here to access/download;Figure;Figure 4.pdf](#)







[Click here to access/download](#)

Video

video 1.avi





[Click here to access/download](#)

Video

video 2.avi

